




Contents lists available at ScienceDirect

## Journal of the Neurological Sciences

journal homepage: [www.elsevier.com/locate/jns](http://www.elsevier.com/locate/jns)

## Miscellaneous Topics 1

522

WFN15-0766

## Miscellaneous Topics 1

**Probing effects of visual motion adaptation on primary visual cortex (V1) excitability using Tms in Bilateral Vestibular Failure (Bvf) patients**H. Ahmad, R.E. Roberts, Q. Arshad, M. Patel, A.M. Bronstein. *Neuro-otology, Imperial College London, London, United Kingdom*

**Background:** Adaptation following BVF is mediated through increased reliance on visual and somatosensory systems. Patients report oscillopsia due to a defective vestibulo-ocular reflex causing retinal slip. No previous studies have directly investigated the effects of visual motion adaptation on visual cortical excitability using TMS in BVF patients.

**Objective:** We proposed that constant exposure to visual motion, and subsequent central adaptation, may decrease the perception of TMS-induced phosphene following visual motion adaptation and correlated this with psychophysical parameters.

**Methods:** 12 BVF patients and 12 age-matched controls were recruited. This was approved by the local research ethics committee. Subjects were positioned in a chair surrounded by an optokinetic (OK) drum. Biphasic TMS pulses were applied at V1 and stationary phosphene threshold (PT) was estimated. Visual motion employed was rightward OK stimuli at 30°/s. Phosphene perception was recorded during baseline motion, followed by 5 minutes of motion adaptation (no TMS) and during post-adaptation. Results were analysed by calculating probability of phosphene perception. All subjects completed oscillopsia scale questionnaires.

**Results:** Baseline PT's were significantly higher in patients ( $p = 0.024$ ) reflecting reduced visual cortical excitability. Lower oscillopsia scores correlated with reduced baseline visual cortical excitability ( $p = 0.009$ ). There was no significant difference between baseline motion and post-adaptation phase in either group ( $p = 0.06$ ).

**Conclusions:** Raised baseline PT's are a possible neurophysiological correlate for clinical observations of reduced (adaptive) visual motion perception in these patients, supported by the correlation with functional levels of oscillopsia. These findings provide evidence for adaptive visuo-cortical mechanisms leading to symptom reduction following BVF.

doi:[10.1016/j.jns.2015.08.594](https://doi.org/10.1016/j.jns.2015.08.594)

523

WFN15-0739

## Miscellaneous Topics 1

**Study of magnetic resonance angiography in cases of central vertigo and its clinical correlation**T.N. Dubey, N. Nahar, A. Thomas. *Internal Medicine, Gandhi Medical College, Bhopal, India*

0022-510X/\$ – see front matter.

**Background:** Syndromal Vertigo can be caused due to either or both of disturbances in vestibular apparatus or its central connections in the brain. Vertebrobasilar haemodynamics correlate closely with central forms of vertigo. Magnetic resonance angiography (MRA) is a noninvasive method that provides angiogram-like images of the intracranial and extracranial arterial blood flow and can be valuable in estimation of vertebrobasilar hemodynamics in patients with central vertigo.

**Objectives:** To assess the significance of MRA as a useful tool for diagnosing different cases of central vertigo. To identify the high risk group patients with Vertebro-basilar insufficiency, stenosis, abnormalities in the posterior circulation vessels that if early diagnosed can possibly prevent serious disabilities in the future.

**Patients and methods:** 37 Patients presenting to neurology department of a tertiary care centre with central vertigo and fulfilling inclusion and exclusion criterion were subjected to MRI and MRA brain and results correlated clinically.

**Results:** Of 37 patients, 33 patients (89.2%) proved to be suffering from vascular causes of vertigo and MRA could pick vascular abnormalities in 31 subjects ( $p$  value 0.004). Sensitivity and specificity of MRA in central vertigo was found to be 93.94% and 75%, respectively. MRA could identify vascular abnormality in 1 patient previously undiagnosed to be vascular (in MRI) but presenting with central vertigo which throws light on the fact that MRA can reveal abnormalities even in cases of isolated vertigo.

**Conclusions:** MRA is a non invasive method to diagnose different cases of central vertigo and be used as a screening examination to evaluate vertebrobasilar haemodynamics, especially in patients suspected to have Vertebrobasilar Insufficiency. It also reveals abnormalities even in cases of 'solo-vertigo' with no observed neurologic abnormalities.

**Declaration:** I have obtained patient and Institutional Review Board approval.

doi:[10.1016/j.jns.2015.08.595](https://doi.org/10.1016/j.jns.2015.08.595)

524

WFN15-0536

## Miscellaneous Topics 1

**Peripheral facial paralysis in an infant with malignant hypertension and suspected neurofibromatosis disease**Z. Albahri, A. Lukeš, P. Rozsival. *Department of Pediatrics, University Hospital Hradec Kralove, Hradec Kralove, Czech Republic*

**Abstract:** Facial nerve palsy is a common malady in children that may be congenital or acquired, hypertension is one of the rare causes of peripheral facial paralysis in children. We present a 10 month old male infant, was first seen with peripheral facial paralysis as the first symptom of malignant hypertension due to renal artery stenosis, the patient had Cafe

au Lait spots and was suspected to have neurofibromatosis disease. The pathogenic mechanisms underlying hypertension-induced facial paralysis has been hypothesized before to lie in the widespread arteriolar injury in the enclosed space of the facial canal.

doi:10.1016/j.jns.2015.08.596

525

WFN15-0063

Miscellaneous Topics 1

Sleep in medical students of Amazonas – Brazil

C.M. Almeida<sup>a</sup>, R. Stabenow<sup>b</sup>, P. Lima<sup>b</sup>, M. Takatani<sup>c</sup>. <sup>a</sup>Department of Neurology, Universidade do Estado do Amazonas, Manaus, Brazil; <sup>b</sup>Universidade Federal do Amazonas, Manaus, Brazil; <sup>c</sup>Department of Neurology, Universidade Federal do Amazonas, Manaus, Brazil

**Objectives:** The study evaluated the quality of sleep and sleepiness among medical students and residents, and the possible association between these variables and extra-curricular activities, sleep habits and regional socio-demographic characteristics.

**Methods:** A total of 153 undergraduate students and residents of the School of Medicine of the Federal University of Amazonas (UFAM) were evaluated through three specific questionnaires: a personal identification and activities performed by the student, the scale of the Pittsburgh Sleep Quality (PSQI) and the Epworth Sleepiness Scale (ESS), and a Sleep Diary.

**Results:** 71.24% of students had poor quality of sleep, with a Pittsburgh Sleep Quality Index overall average score of  $6.95 \pm 2.38$ ; The analysis of the Epworth Sleepiness Scale found that 41.17% of students and residents showed scores greater than 10 points, and 7.84% showed scores greater than 15 points, considered as mild to moderate drowsiness respectively. Residents showed a significantly greater percentage of excessive sleepiness (75%) compared to students from 6th to 9th semesters (46.77%) and 1st to 5th semesters (34.14%) ( $p = 0.029$ ). The average amount of sleep per night within this sample group was 5 h 39 min.

**Conclusion:** These results suggest that medical school students and residents have poor sleep quality and show daytime sleepiness, and that the Amazonian climate can be an aggravating factor for this. Thus, actions are necessary to minimize the negative effects of sleep deprivation, such as a limit of work hours per week, and implementation of good practices of sleep hygiene.

doi:10.1016/j.jns.2015.08.597

526

WFN15-0216

Miscellaneous Topics 1

Sleep quality among male medical students in King Khalid University

M. Almetrek<sup>a</sup>, M. Alqahtani<sup>b</sup>, A. Alsamghan<sup>c</sup>, H. Alqahtani<sup>c</sup>, M. Alshahrani<sup>c</sup>, S. Alshahrani<sup>c</sup>, F. Alshahrani<sup>d</sup>. <sup>a</sup>Health Promotion and Education, Khamis Mushayte, Kingdom of Saudi Arabia; <sup>b</sup>Primary Health Care Sectors Administration, Abha, Kingdom of Saudi Arabia; <sup>c</sup>Family and Community Medicine Department, College of Medicine, King Khalid University, Abha, Kingdom of Saudi Arabia; <sup>d</sup>Family and Community Medicine Department, Armed Forces Hospital Southern Region, Khamis Mushayte, Kingdom of Saudi Arabia

**Background:** Medical students are exposed to a significant pressure due to academic challenges that can affect their sleep quality adversely.

**Objectives:** To assess the sleep quality of male students in the College of Medicine, King Khalid University, Saudi Arabia.

**Material and Methods:** a cross-sectional analytical study was conducted including representative sample through stratified sampling technique of male students registered for the academic year 2014 in College of Medicine, King Khalid University, Abha, KSA. A Self-administered questionnaire was used based on Pittsburgh Sleep Quality Index (PSQI).

**Results:** There were 232 responses from the total population of 267 students with a response rate of 86.9%. Their age ranged between 18 and 25 years with a mean of 21.3 years and standard deviation of 2.4 years. Most of them (78.4%) were poor sleepers during the past month, based on Global PSQI Score. Sleep complaints were reported by 77.2% of the participants. Of them, 19.6% frequently suffered from difficulty falling asleep. Difficulty staying asleep and frequent awakening from sleep were frequently reported by 21.8% and 18.5% of them, respectively.

**Conclusion:** Poor sleep quality is a common problem affecting most of male students in College of Medicine, King Khalid University, Abha, KSA. It is more reported among students of final academic years and smokers. Sleep complaints have consequences on physician's work, social and other important parts of life. Further studies for getting better sleep quality and its recommendations should be done.

doi:10.1016/j.jns.2015.08.598

527

WFN15-0023

Miscellaneous Topics 1

Intrathecal baclofen pump: KSA experience

Y. Awaad<sup>a</sup>, T. Rizk<sup>b</sup>, R. Tamer<sup>b</sup>. <sup>a</sup>Pediatric Neurology, Oak wood, MI, USA; <sup>b</sup>Pediatric Neurology, Al-Takhassusi Hospital, Riyadh, Saudi Arabia

**Abstract:** Increasingly, spasticity is managed with surgically implanted Intrathecal Baclofen pumps. Intrathecal Baclofen pump revision surgery unrelated to programmable pump end-of-life is not uncommon, requiring special attention during pre-, intra-, and post-operative management. We aimed to identify and describe complications of Intrathecal Baclofen pump as well as to report avoidance and management of complications.

**Methods and Materials:** Through 2007–2010, at the department of neurosurgery, King Fahd Medical City, Intrathecal Baclofen pumps were implanted in 43 patients; 21 children versus 22 adults; 14 revision surgeries were performed in 10 patients. We evaluated reasons for revision surgeries and diagnostic work-up requirements.

**Results:** Ten out of 43 primary-implant-patients required 14 revisions; 8 patients had only 1 revision procedure while 2 patients had multiple revision procedures. Complications ranged between: Implant infections in 8 cases; 1 paternal cause, 3 post dehiscence, 1 post rejection, 1 post trauma, 1 post hematoma and 1 pure infection. CSF leakage in one case.

**Conclusions:** Intrathecal Baclofen pumps, although very gratifying, have a high, technique-related complication incidence during implant life. Meticulous technique, high clinical suspicion, appropriate work-up, and timely surgical management can reduce surgical complications of Intrathecal Baclofen pump implantation.

doi:10.1016/j.jns.2015.08.599

528

WFN15-0024

Miscellaneous Topics 1

Botulinum toxin-A in postoperative pediatric stiff hips

R. Tamer, Y. Awaad. *Pediatric Neurology, Al-Takhassusi Hospital, Riyadh, Saudi Arabia*

**Abstract:**

**Objective:** The aim of the study is to show the functional contribution of botulinum toxin-A in the treatment of postoperative pediatric stiff hips.

**Methods:** Four pediatric patients with postoperative stiff hips were included. Three patients with complicated developmental dysplasia of the hip after multiple revision surgeries, and a case of cerebral palsy after hip surgery were given botulinum toxin injections in selected muscles as an adjunctive therapy to the standard orthopedic and rehabilitation management.

**Results:** All patients experienced significant reduction in pain with significant improvement in posture, range of motion and mobility.

**Conclusion:** The preliminary results of Botulinum toxin-A injection when given to selected muscles seems to be promising in relieving pain and improving range of motion in pediatric patients with postoperative stiff hips. It may be considered as an option in the treatment of difficult cases of postoperative stiff hips refractory to physiotherapy.

doi:10.1016/j.jns.2015.08.600

529

WFN15-0694

**Miscellaneous Topics 1****Surplus value of the video-head impulse test in patients with vestibular schwannoma**

A. Beynon. *ENT, Radboud UMC, Nijmegen, The Netherlands*

**Background:** To examine the impact effect of a vestibular schwannoma on vestibular function, patients undergo standard electronystagmography (ENG) assessment. Recently, video-Head Impulse Test (vHIT) is applied to capture fast eye movements with at least 100 images per second, obtaining not just overt, but also covert correction saccades. In contrast to other tests, it allows us to easily assess vertical posterior and anterior semicircular canal (SCC) functionality.

**Aim & methods:** As tumor position and size have implications on balance function, a retrospective study was set up, including 92 patients with a unilateral vestibular schwannoma (VS), who underwent standard ENG. The aim of this study is to investigate surplus of vHIT assessing all SCC in relation to vestibular loss in VS patients. Additionally, conventional caloric irrigation data (NB. only horizontal canals) was obtained and compared to vHIT outcomes.

**Results:** In 78% of patients, vHIT evoke reliable responses in all 6 semicircular canals. The anterior canal was never affected on its own, nor in combination with posterior canal. When two or more canals were affected, the lateral canal was always involved. In contrast, caloric testing did not provide sufficient information to assess patient's vestibular function, since the role of the posterior canal is underestimated.

**Conclusion:** In conclusion, the surplus value of vHIT is obvious in vestibular schwannoma patients in addition to caloric testing, since vHIT provides useful extra information of all 3 semicircular canals, the posterior canal in particular, tumor size and subjective complaints.

doi:10.1016/j.jns.2015.08.601

531

WFN15-1018

**Miscellaneous Topics 1****Manifestations of spinal melanoma metastases: case presentation and literature review**

P. Cairola<sup>a</sup>, P. Sandoval<sup>b</sup>, H. Steinsleger<sup>b</sup>, A. Tardivo<sup>b</sup>, M. Benes<sup>c</sup>.  
<sup>a</sup>Neurologia, Hospital Carlos G Durand, CABA, Argentina; <sup>b</sup>Neurocirugia, Hospital Carlos G Durand, CABA, Argentina; <sup>c</sup>Anatomía patológica, Hospital Carlos G Durand, CABA, Argentina

**Introduction and objectives:** Spinal metastases are common manifestation of solid tumors, with the frequency of melanoma from 1–4%. The symptoms are directly related to their location. The present work's objective is to extend the differential disease's spectrum to insist on the diagnosis for the treatment of choice, resection according the stage.

**Material and methods:** Analysis of medical records of patients diagnosed with spinal metastases from melanoma in Carlos G Durand Hospital, during the period 2010 to 2013. Case 1: male 32 years, paraplegia, nodular lesions in the breast region and right arm. Imaging (MRI) evidence lesions vertebral body which affected the spinal channel, biopsy lesions linkable with metastatic melanoma. Case 2: male 68 years, right back pain. MRI evidences vertebral body involvement with D4-D5 channel invasion. No evidence of skin lesion. biopsy findings with melanoma. Case 3: female, 48 years, with cervicobrachialgia with a history of melanoma. MRI was performed with of intramedullary lesion C6–C7. Extirpation surgical pathology diagnosis with melanoma.

**Conclusion:** Melanoma is a skin neoplasm originated from the neural crest, 4–5% of all primary melanomas that are not derived from skin. In our series of cases, skin lesions could not be detected in a patient. Early and accurate diagnosis allows us to use adjuvant treatment.

doi:10.1016/j.jns.2015.08.602

533

WFN15-0987

**Miscellaneous Topics 1****Neurolymphomatosis: a rare cause of mononeuritis multiplex**

B. Das<sup>a</sup>, M.K. Goyal<sup>a</sup>, M. Modi<sup>a</sup>, V. Lal<sup>a</sup>, S. Vyas<sup>b</sup>, B.D. Radotra<sup>c</sup>, B.R. Mittal<sup>d</sup>.  
<sup>a</sup>Dept. of Neurology, PGIMER, Chandigarh, India; <sup>b</sup>Dept. of Radiology, PGIMER, Chandigarh, India; <sup>c</sup>Dept. of Pathology, PGIMER, Chandigarh, India; <sup>d</sup>Dept. of Nuclear Medicine, PGIMER, CHANDIGARH, India

**Abstract:**

**Background:** Neurolymphomatosis, direct invasion of peripheral nerves by lymphoma cells is a rare presentation of lymphoma. We report four cases of Neurolymphomatosis who presented to us with peripheral neuropathy.

**Objective:** To describe four patients of Neurolymphomatosis, presenting as mononeuritis multiplex.

**Patients and results:** Four elderly gentlemen presented to us during last one year. While one presented with sciatic mononeuropathy, other three presented with clinical picture suggestive of mononeuritis multiplexa. In two patients diagnosis was made by nerve biopsy, in one at autopsy and in one by ancillary investigations including PET. PET showed increased uptake in different nerve trunks in all three patients in whom it was carried out. Nerve conduction studies revealed axonal neuropathy in two patients and mixed axonal-demyelinating neuropathy in two. All the four patients received incorrect diagnosis before evaluation in our center.

**Conclusions:** Neurolymphomatosis is a rare cause of mononeuritis multiplex, which need to be kept in mind while evaluating patient with mononeuritis multiplexa. Detailed investigations including whole body PET scan and nerve biopsy help in reaching a correct diagnosis in majority of patients.

doi:10.1016/j.jns.2015.08.603



534

WFN15-0308

**Miscellaneous Topics 1****Clinical features and therapy analysis of 208 patients with psychogenic dizziness**

Q. Dong, X. Qi. Department of Neurology, Navy General Hospital of PLA, Beijing, China

**Objective:** To summarize the clinical features and the treating methods in 208 cases with psychogenic dizziness and to accumulate clinical experience and to direct clinical work.

**Methods:** 208 patients with psychogenic dizziness who visited department of neurology were analysed according to age, sex, symptoms, laboratory examinations, therapy and prognosis.

**Results:** 208 cases (152 were female, 56 were male) were between ages 17 to 77 (the average onset age was 51.98 years). It was more frequently taken on adult females. There were 3 types according to different clinical features and therapy prognosis: anxiety and depression type, hysteria type and mania type. There were abnormal changes in Self-rating Anxiety Scale (SAS), Self-Rating Depression Scale (SDS) and Bech-Rafaelson Mania Rating Scale (BRMS). The drug increasing the concentration of excitatory has a good therapeutic efficacy on anxiety and depression type. Alluding cure has notable effect on hysteria type and mood stabilizer has notable effect on mania type.

**Conclusions:** Patients with psychogenic dizziness who visited department of neurology were more frequently taken on adult females. It can be divided into three types: anxiety and depression type, hysteria type and mania type. Each has their own characteristics on clinical features and laboratory examinations and they require different therapeutic regimens.

doi:10.1016/j.jns.2015.08.604

535

WFN15-0078

**Miscellaneous Topics 1****Neuropsychiatric consequences & traffic safety in patients with sleep apnea syndromes**

A. Büttner-Teleaga. Institute of Cognitive Science, Woosuk University, 565-701, Samrye-up, Wanju-gun, Jeonbuk, South Korea; Department of Psychiatry, University Witten-Herdecke, 58448 Witten, A.-Herrhausen-Str. 50, Germany

**Introduction:** Sleep Breathing Disorders (SBD), esp. Sleep Apnea Syndromes (SAS) lead to a lot of physical problems like hypertension and arrhythmias and mostly even to neuropsychiatric consequences like Brain atrophy, Depression, Anxiety and Insomnia. Apart from a multitude of physical complaints, SAS patients suffer from Excessive Daytime Sleepiness (EDS), reduced sustained attention, limited memory processes and cognitive functions and reduced Quality of Life (QoL). Among other aspects, such a decline in performance influences the persons affected in their ability to drive a car. Considering the poor knowledge of reliable facts of aetiology in neuropsychiatric diseases could show unusually clean-cut conditions of interference with the mechanism of mental and sensory-motor plasticity.

**Methods:** In our study we used neuropsychological and neuropsychiatric methods in different patient groups in a sleep laboratory. Over the past 5 years we have been testing more than 4000 patients. During admission to the clinic, all patients were selected according to their clinical diagnosis (ICD-10) and all patients were examined neurologically, neuro-psychologically and psychiatrically. All test persons must not suffer from any severe psychiatric disorders. The study was carried out involving all groups of randomly selected patients with SAS on a number of neuropsychiatric parameters.

**Findings:** Testing of neuropsychiatric diseases and difficulties and quality of life revealed a highly significant difference between healthy persons and SAS patients ( $p < 0.05$ ). Examination of specific domains of neuropsychiatric diseases, memory processes, driving ability and quality of life showed significant differences in patients with SAS. In all dimensions of neuropsychiatric diseases, memory processes and quality of life, untreated SAS patients had inferiority scores than those who had undergone therapy. After more than 6 weeks nCPAP therapy, the neuropsychiatric diseases of the SAS patients, memory processes, driving ability and quality of life improved to a significant degree ( $p < 0.05$ ). Analysis of the degree of severity showed for SAS that on the whole, there is a significant difference concerning neuropsychiatric diseases, memory processes, driving ability and quality of life.

**Discussion:** The study revealed that patients with SAS show neuropsychiatric problems and deficits concerning their vigilance achievements, their memory processes and their quality of life. The improvement of vigilance achievements and memory processes show a lower driving fitness (traffic safety) in untreated patients and increasing traffic safety in treated patients. In summary, based on our results, it is to be said that although a continuous nCPAP therapy improves the SAS symptoms; neuropsychiatric consequences, memory processes, driving ability and the quality of life require longer-term degeneration.

doi:10.1016/j.jns.2015.08.605

536

WFN15-1141

**Miscellaneous Topics 1****Acute blindness following sever metabolic acidosis: case report**

H. Egila<sup>a</sup>, M. El-adalany<sup>b</sup>, A.D.E.L. El-badaray<sup>b</sup>, M. Gomaa<sup>a</sup>. <sup>a</sup>Department of Neurology, Faculty of Medicine, Mansoura University, Mansoura, Egypt; <sup>b</sup>Department of Radiology, Faculty of Medicine, Mansoura University, Mansoura, Egypt

**Objective:** To report MRI brain and ophthalmological finding in a case of an adult male with sever metabolic acidosis due to sepsis.

**Background:** Inhibition of cytochrome oxidase in retina due to metabolic acidosis. Additionally affection of visual pathway might further aggravate the deterioration due to ischaemic changes.

**Patients/methods:** We are reporting 26-year-old male who presented with disturbed consciousness, fever and shock 2 days following laparoscopic removal of stone and drainage of perinephric abscess, patient was diagnosed as septic shock and receive proper treatment then the Clinical presentation was unique due to after patient regain consciousness he complain of blindness and there was dilated fixed pupil with intact power and sensation.

**Results:** A 26 year old male presented with acute blindness following correction of sever metabolic acidosis and septic shock and the initial fundoscopic examination in both eyes showed moderately swollen, hyperemic optic disc and dilated, unresponsive pupillary reflex. Brain MRI performed on day 3 demonstrated bilateral abnormal signal of putamen which is sequel of metabolic acidosis. Intravenous corticosteroids were administered 1 gm/day for 5 days with no improvement.

**Conclusions:** To the best of our knowledge this is the first case described with such course of blindness following sever metabolic acidosis and MRI brain finding that mimic ethanol toxicity.

So in case of methanol toxicity the effect is mainly on acidosis not on formic acid by name that result from metabolism of methanol.

doi:10.1016/j.jns.2015.08.606

537

WFN15-1150

## Miscellaneous Topics 1

## Isolated spinal neurofibromatosis in (nf1): case report

H. Egila<sup>a</sup>, A. AbdEl-khalek<sup>b</sup>, A. Abd El-Naby<sup>a</sup>, M. Gomaa<sup>a</sup>. <sup>a</sup>Department of Neurology, Faculty of Medicine, Mansoura University, Mansoura, Egypt; <sup>b</sup>Department of Radiology, Faculty of Medicine, Mansoura University, Mansoura, Egypt

**Objective:** To represent a case of spinal neurofibromatosis(NF) located in the dorso-lumbo-sacral regions with no other criteria of (NF1).

**Background:** Spinal neurofibromas with clinical implications are reported in about 5% of NF1 patients. This estimate may be too low, since, MRI studies in randomly selected asymptomatic NF1 patients show that spinal neurofibromas are found in up to 38% of patients.

**Patients/Methods:** Case report and review of a patient with isolated Spinal neurofibromatosis.

**Results:** A 28-year-old man with a 3-year history of bilateral foot drop. Recently, develop urine and stool retention with on other clinical neurological manifestations.MRI of the dorso-lumbo-sacral spine showed paraspinal soft tissue masses with intra and extra spinal compartments associated with widening of neural foramina of lumbar and sacral regions and multiple variable sized renal cysts. True cut biopsy from the lesion support diagnosis of neurofibroma.

**Conclusions:** Symptomatic spinal neurofibromas are the main clinical finding in patients with familial spinal neurofibromatosis (FSNF) but due to the lack of other affected family members the diagnosis of FSNF may not unequivocally be made.

Furthermore, our patient does not fulfill NIH criteria for NF1. However, the severe spinal involvement in this patient is striking and may indicate that this patient belongs to a distinct clinical entity of spinal neurofibromatosis.

doi:10.1016/j.jns.2015.08.607

538

WFN15-1361

## Miscellaneous Topics 1

## Kleine–Levin syndrome

S. Gomes. Department of Neurology, B. Portuguesa, Sao Paulo, Brazil

**Introduction:** Kleine–Levin Syndrome (KLS) is a rare disorder, characterized by relapsing remitting episodes of severe hypersomnia, cognitive impairment, apathy, derealisation, and psychiatric and behavioral disturbances. Boys are more frequently affected than girls.

**Objective:** Report on e cases of KLS. Few days after alcoholic libation use a 21 years old boy presented severe hypersomnia, sleeping over 13 hours per day, and behavioral disturbances lasting 9 days. When awake he exhibited apathy and derealisation. Symptoms relapsed every ten months, and each lasted for 20 to 30 days. Epworth Sleepiness Scale (ESS) scored 23 during hypersomnia period and 5 in usual days. Misdiagnosed as depression and epilepsy at onset. Magnetic Resonance Imaging (MRI) showed cerebral mass due right acoustic neuroma. Toxicology, hormonal and laboratory tests were in the normal range. Inflammatory biomarkers were negative. An overnight polysomnography (PSG) and multiple sleep latency test (MSLT) ruled out narcolepsy. Single-photon emission computed tomography (SPECT) was performed and showed a left thalamic hypoperfusion.

**Discussion:** KLS is often misdiagnosed as depression, bipolar disorder, psychosis, seizures, or intoxication, partly because it is rare and infrequently encountered by clinicians. The first episode of hypersomnia is often triggered by an infection, head trauma or alcoholic libation. Neurologic and psychiatric assessment combined with SPECT provides a guide to avoid misdiagnosis in KLS cases.

doi:10.1016/j.jns.2015.08.608

539

WFN15-1097

## Miscellaneous Topics 1

## Extranodal NK/T cell lymphoma in an 18 year-old female presenting with subacute spastic paraparesis: a case report

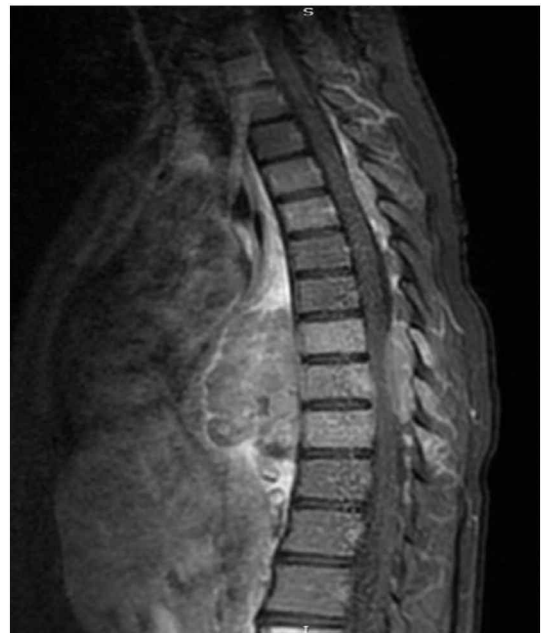
R.P. Gonçalves, A.L.R. Palmeira, M.V. Raffo, C.A.J. Monsalve, C.M. Carpenedo, T. Pigozzo, M.F. Gomes, M.C. Ribeiro. *Serviço de Neurologia, Universidade Federal de Ciências da Saúde de Porto Alegre, Porto Alegre, Brazil*

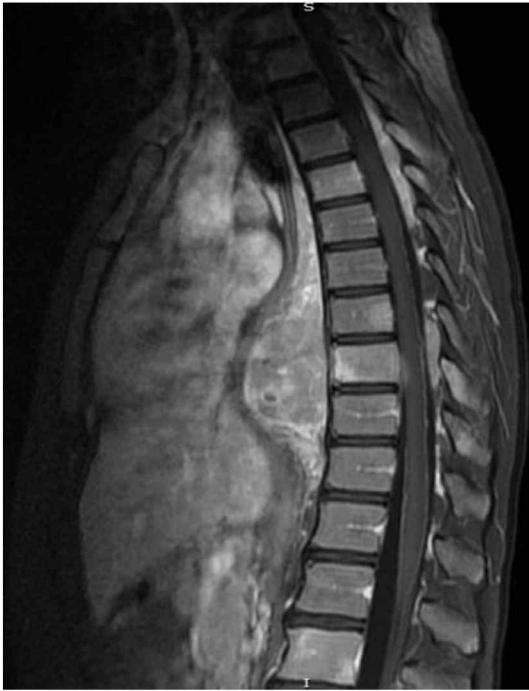
**Background:** Extranodal NK/T cell lymphoma is a rare group of proliferative disorders, rapidly-evolving and with poor prognosis. CNS involvement is very uncommon with a few cases associated with spinal involvement.

**Objective:** To report a case of a spinal involvement by an extranodal NK/T cell lymphoma.

**Case report:** A 18 years-old female with a history of idiopathic ulcerative rectocolitis, on mesalazine and azathioprine treatment was admitted due to subacute loss of strength and sensitivity of the lower limbs. Examination showed spastic paraparesis and hypoesthesia of the lower limbs, with a T7–T8 sensory level. Sphincter control was preserved, and there were no other relevant findings. MRI of the neuroaxis, demonstrated an anterior paravertebral heterogeneous contrast-enhancing lesion (Fig. 1). After 20 days it was performed a newer MRI of the neuroaxis, with worsening of the lesion and spinal compression (Fig. 2). Whole-body CT scan revealed no alterations. A CT-guided biopsy was performed with anatomy and histopathological results of NK/T cell lymphoma. EBV and HTLV I/II PCR were negative. Bone marrow biopsy did not show alterations as so whole-body PET scan. Chemotherapy (SMILE protocol) was began, and patient follow-up showed gradual improvement of strength.

**Discussion:** Extranodal NK/T cell lymphoma is a rare disorder, and usually presents with nasopharyngeal mass – less commons are testicle and skin involvement. It is strongly correlated with EBV infection. Prognosis is poor despite adequate treatment. There are few cases of the literature concerning CNS involvement, although is generally associated with others primary sites.





doi:10.1016/j.jns.2015.08.609

**540**  
**WFN15-0097**  
**Miscellaneous Topics 1**  
**High resolution imaging of the optic nerve and retina in optic nerve hypoplasia**

I. Gottlob, A. Pilat, D. Sibley, R.J. McLean, A.F. Proudlock. *The University of Leicester Ulverscroft Eye Unit, University of Leicester, Leicester, United Kingdom*

**Background:** Little is known about optic nerve and retinal morphology in optic nerve hypoplasia (ONH).

**Objective:** To investigate optic nerve and macular morphology in patients with ONH using spectral-domain optical coherence tomography (SD-OCT).

**Materials and methods:** High-resolution horizontal SD OCT scans were obtained in 16 participants with ONH (10 females and 6 males; mean age  $17.2 \pm 16.22$ , 6-bilateral involvement) and 16 gender, age and ethnicity-matched healthy controls.

**Results:** Patients with ONH had significantly smaller discs as compared to unaffected eye and healthy controls ( $p < 0.03$  for both), horizontal cup diameter ( $p < 0.02$  for both), and cup depth ( $p < 0.02$  and  $p < 0.002$ , respectively). In the macula significantly thinner retinal nerve fibre layer (RNFL, nasally), ganglion cell layer (GCL, nasally and temporally), inner plexiform (IPL, nasally) and outer nuclear layers (ONL, nasally), inner segment (IS, centrally and temporally) were found in patients with ONH as compared to the control group ( $p < 0.05$  for all comparisons). Continuation of significantly thicker GCL, IPL and OPL in the central retinal area (i.e. foveal hypoplasia) was found in more than 80% of patients with ONH. Clinically unaffected eyes of patients with ONH showed mild features of underdevelopment.

**Conclusions:** Our study provides for the first time evidence of retinal changes in ONH. In addition to thinning of retina layers mainly involving RNFL and GCL, foveal maldevelopment was observed in patients with ONH. Optic nerve and foveal parameters measured using OCT showed high sensitivity and specificity for detecting ONH demonstrating their useful for clinical diagnosis.

doi:10.1016/j.jns.2015.08.610

**541**  
**WFN15-0044**  
**Miscellaneous Topics 1**  
**Sleep disorder in patients with multiple sclerosis**

D. Grass Fernandez<sup>a</sup>, J.A. Cabrera Gomez<sup>b</sup>, L. Morales Chacon<sup>b</sup>, A. Gonzalez Quevedo<sup>c</sup>. <sup>a</sup>Nursing, International Center for Neurological Restoration (CIREN), Havana, Cuba; <sup>b</sup>MEDICAL, International Center for Neurological Restoration (CIREN), Havana, Cuba; <sup>c</sup>MEDICAL, Institute of Neurology and Neurosurgery, Havana, Cuba

**Introduction:** Multiple sclerosis (MS) is a neurological disease that usually presents in young adults, whose origin is unknown. It is the second leading cause of disability following car accidents. Usually people with MS do not complain of sleep disorders, only do so when they are asked.

Sleep disorders in these patients are diagnosed below and can be up to three times more frequent than in the rest of the population. Some patients have more daytime sleepiness, increased sleep latency and nighttime awakenings.

A therapeutic alternative for patients with MS and MS PP BR is the use of Rebif 44mcg.

Are refueled as one of the reactions of this the occurrence of insomnia medicine target

- Assess the condition of sleep in patients with multiple sclerosis (MS) treated with interferon beta 1 using scales and questionnaires.

**Materials and methods:** We selected 88 patients with a diagnosis of multiple sclerosis which were applied to different scale and questionnaire are dream like sleep questionnaire, morningness and eveningness questionnaire, Epworth scale and insomnia medical instrument.

Findings

- Patients with multiple sclerosis outbreak under treatment with interferon beta remission 1a (Rebif 44mcg) have a range of morningness and eveningness intermediate to moderate morning.
- Preliminary survey results reveal evaluated no significant sleep disorder in these patients.

doi:10.1016/j.jns.2015.08.611

**543**  
**WFN15-0462**  
**Miscellaneous Topics 1**  
**Comparison of reposition rate between postheadshaking modified sermont maneuver and postvibration modified sermont maneuver in apogeotropic horizontal BPPV**

H. Han<sup>a</sup>, D. shin<sup>a</sup>, H. kang<sup>b</sup>. <sup>a</sup>Department of Neurology, Saint Carollo Hospital, Jeollanam-do, Korea; <sup>b</sup>Department of Neurology, Chosun University School of Medicine, Jeollanam-do, Korea

Benign paroxysmal positional vertigo (BPPV) is one of the most common disorders causing dizziness. Horizontal Canal (HC)-BPPV has been said to account for 5–30% of all BPPV cases. However, HC-BPPV now appears to be more prevalent than was previously thought. The apogeotropic type is usually persistent, resistant to reposition maneuver, and its pathophysiology is cupulolithiasis in majority. We compare reposition rate between headshaking with modified sermont maneuver and vibration with modified sermont maneuver. The subjects were 64 patients with apogeotropic type of HC-BPPV who were diagnosed by the supine roll test using videonystagmography. We perform modified sermont maneuver after headshaking in 33 patients and the others were



performed modified sermont maneuver after vibration. The patient with remaining vertigo after maneuver was retreated with same method. After 1 week, we interviewed all the patients using call whether vertigo was subside. 4 patients had vertigo but they didn't come to hospital because of private reason (3 in headshaking group and 1 in vibration group). We counted the number of performance and compare with headshaking group and vibration group. Fifty twice maneuvers were performed in headshaking group and fiftieth maneuvers were performed in vibration group. The more vertigo is severe, the less maneuver was performed in both group. There is no significant difference in recurrence rate between headshaking group and vibration group.

doi:10.1016/j.jns.2015.08.612

544

WFN15-1544

Miscellaneous Topics 1

**Cowden syndrome: case report of a neurological case**

A. Hazim, M.A. Rafai, Y. Habtany, F.Z. Mouni, F.Z. Mouni, B. El Moutawakil, H. El Otmani, I. Slassi Sennou. *Department of Neurology, CHU IBN ROCHD, Casablanca, Morocco*

**Introduction:** Cowden syndrome is rare disease in neurology and particular with regards to its severity and clinical discretion.

**Objectives:** Reporting a Cowden syndrome case revealed by neurological manifestation.

**Case Report:** We report the case of a 33 years old female patient referred for isolated right eye painless ptosis, non-fluctuating, with fast installation but without decreased visual acuity. The clinical examination revealed a macrocephaly and a discrete exophthalmos. However, no oculomotor nerve impairment nor papilledema were found and the ice pack test was negative. The dermatological examination highlighted papular lesions evolving since young age with diffuse hamartomatous lesions. Brain MRI showed a large right suprasellar tumor, intrusive and compressing the levator palpebrae superioris muscle, which may be related to hamartoma.

**Discussion and conclusion:** The cerebellar location of hamartoma in Cowden syndrome is the most frequent; however, other locations may be found resulting in wide clinical varieties. An early and multidisciplinary approach should be systematic in order to avoid progression to other neoplasias.

doi:10.1016/j.jns.2015.08.613

545

WFN15-0314

Miscellaneous Topics 1

**Myxopapillary ependymoma: a case report of wide metastasis**

J.J. Huang<sup>a</sup>, Y. Wang<sup>a</sup>, J.Z. Yin<sup>a</sup>, R.F. Wu<sup>a</sup>, L.B. Li<sup>a</sup>, C.G. Ma<sup>b</sup>, J.Z. Yu<sup>b</sup>, B.G. Xiao<sup>c</sup>. <sup>a</sup>Department of Neurosurgery, General Hospital Datong Coal Mine Group, Datong, China; <sup>b</sup>Department of Neurosurgery, Medical School Shanxi Datong University, Institute of Brain Science, Datong, China; <sup>c</sup>Department of Neurology, Huashan Hospital, Institutes of Brain Science, State Key Laboratory of Medical Neurobiology, Shanghai, China

**Background:** Myxopapillary ependymoma (MPE) is a rare neoplasm found predominantly in the sacro-coccygeal region in adults. The typical pathological changes were arrangement of cuboidal or spindle-shaped tumor cells around vascularized and myxoid stromal cores in a papillary-radial type. A large quantity of mucus accumulated between tumor cells and vessels or within microcysts accompanied by vascular thickness and hyalinization.

**Objective:** To explore the effects of surgical margins at surgery and postoperative radiotherapy on tumor recurrence and prognosis.

**Patients and methods:** We describe a large spinal ependymomas invading the dura mater and the vertebra from C7 to S3, which is 48 cm of the cumulative length. The patient underwent gross total resection of the tumor without damage to the spinal cord confirmed by subsequent adjuvant radiotherapy. The lesion was classified as grade 1 ependymoma according to histological examination.

**Results:** The tumour was surgically resected. After 1 week, muscle strength of legs was recovered, and radicular pain was disappeared. After 3 months, the function in bowel and bladder was recovered. After 3 years of following-up, patients can engage in general work. Follow-up MRI examinations revealed no disease progression or new spinal lesions at year 4 after the surgery.

**Conclusion:** MPEs are likelihood for tumor local and disseminated recurrence. The first operation is critical, microscopic dissection along with the tumor and arachnoid interface is crucial to cut all tumors. The best treatment for this lesion is gross total resection and adjunctive radiotherapy is necessary in cases of malignant-change.

doi:10.1016/j.jns.2015.08.614

546

WFN15-0276

Miscellaneous Topics 1

**Visual disturbances in familial forms of multiple sclerosis**

E. Ioyleva, M. Krivosheeva. *Department of Neuroophthalmology, S. Fyodorov Eye Microsurgery Federal State Institution, Ministry of Health, Moscow, Russia*

**Background:** According to various studies, with the familial form of the disease opening symptoms are visual, oculomotor and sensory disorders, concordance with respect to the type of the disease.

**Objective:** To explore the visual disturbances in the case of a familial form of MS.

**Materials and methods:** Sister (38 years) with a history of ON, the first manifestation of 22 years of age – ataxia and nystagmus. Brother (27 years) the first manifestation of optic neuritis OD.

**Methods:** RC-5000 «Tomey», OCT on Cirrus HD-OCT; HRT on Humphrey HFA II-750i on program 10-2; Microperimetry on MP-1, MRI of the brain and orbits (Siemens Magnetom Symphony 1.5 TI).

**The results:** The sister was significant damage to the central nervous system with the significant visual and neurological deficit.

**Diagnosis:** relapsing–remitting MS, cerebrospinal form, optic nerve atrophy. Visus OU 0.01 n/c. OCT – Average RNFL Thickness OD 66 µm, OS 65 µm.

Average GCL + IPL thickness OD 53 µm, OS 55 µm. Brother–Diagnosis: MS cerebrospinal form, optic neuritis. Visus 0,1 with corr. According Microperimetry mean Sensitivity OD 5,3 Db, mean Defect – 10,1 Db. OCT Average RNFL Thickness 91 µm, Average GCL + IPL Thickness 83 µm. MRI revealed multiple foci of demyelination and one active focus 8 mm in diameter in the projection of the right optic nerve.

**Conclusion:** At the first manifestation of optic neuritis and family history of MS need to consult a neurologist, brain MRI and orbits, genetic examination.

doi:10.1016/j.jns.2015.08.615

547

WFN15-0863

Miscellaneous Topics 1

**Hypoxic preconditioning-induced mitochondrial protection is not disrupted in MTDNA T8993G mutation-induced F1F0-ATP synthase defect cybrids: the role of the MPT**

M. Jou<sup>a</sup>, T. Peng<sup>b</sup>. <sup>a</sup>Department of Pharmacology, Chang Gung University, Taoyuan, Taiwan; <sup>b</sup>Department of Neurology, Chang Gung Memorial Hospital, Keelung, Taiwan

Transient opening of the mitochondrial permeability transition pore plays a crucial role in hypoxic preconditioning-induced protection. Recently, the cyclophilin-D component of the mitochondrial permeability transition pore has been shown to interact with and regulate the F1F0-ATP synthase. However, the precise role of the F1F0-ATP synthase and the interaction between cyclophilin-D and F1F0-ATP synthase in the mitochondrial permeability transition pore and hypoxic preconditioning remain uncertain. Here we found that a 1-h hypoxic preconditioning delayed apoptosis and improved cell survival after stimulation with various apoptotic inducers including H<sub>2</sub>O<sub>2</sub>, ionomycin, and arachidonic acid in mitochondrial DNA T8993G mutation (NARP) osteosarcoma 143B cybrids, an F1F0-ATP synthase defect cell model. This hypoxic preconditioning protected NARP cybrid cells against focal laser irradiation-induced oxidative stress by suppressing reactive oxygen species formation and preventing the depletion of cardiolipin. Furthermore, the protective functions of transient opening of the mitochondrial permeability transition pore in both NARP cybrids and wild-type 143B cells can be augmented by hypoxic preconditioning. Disruption of the interaction between cyclophilin-D and F1F0-ATP synthase by cyclosporin A attenuated the mitochondrial protection induced by hypoxic preconditioning in both NARP cybrids and wild-type 143B cells. Our results demonstrate that the interaction between cyclophilin-D and F1F0-ATP synthase is important in the hypoxic preconditioning-induced cell protection. This finding improves our understanding of the mechanism of mitochondrial permeability transition pore opening in cells in response to hypoxic preconditioning, and will be helpful in further developing new pharmacological agents targeting hypoxia-reoxygenation injury and mitochondria-mediated cell death.

doi:10.1016/j.jns.2015.08.616

548

WFN15-0938

#### Miscellaneous Topics 1

### Decreased network coherence in the slow wave frequency band in patients with idiopathic REM sleep behavior disorder

K. Jung, B. Lee, D. Jung, B. Lyu, J. Kyong, T. Kim, J. Byung, J. Sunwoo.  
Department of Neurology, Seoul National University, Seoul, Korea

**Background:** Idiopathic REM sleep behavior disorder (iRBD) is considered as a prodromal symptom of synuclein-associated neurodegenerative disorders such as Alzheimer's dementia. Though EEG slowing and network alteration are the clear signs of neurological disorders, it remains unclear how these detrimental neurobiological changes are reflected in the functional connectivity of the brain network in iRBD.

**Objective:** We aimed to compare inter- and intra-hemispheric functional connectivity in the network between iRBD and healthy control groups.

**Patients and methods:** Ten patients with iRBD (mean age 71.2 ± 7.3 years old) and five healthy control subjects (mean age 70.5 ± 6.7 years old) participated in the study and gave written consents for voluntary participation. The entire study was carried out with the accordance of the institutional review board. Electroencephalogram was recorded during wake resting state. Relative power of the discrete frequency band was obtained, and inter- and intra-hemispheric spectral coherence was compared between groups. For assessing global cognition, mini-mental state examination package (MMSE) was used.

**Results:** MMSE and the relative spectral power did not differ between groups. However, the iRBD group showed remarkably decreased inter-hemispheric coherence in the central and parietal regions and intra-hemispheric coherence in the frontotemporal and frontoparietal regions, both in the delta frequency band, compared to the control group.

**Conclusions:** Our study suggests that network connectivity is altered in patients with iRBD despite the absence of changed cognition, specifically in the lower frequency band.

doi:10.1016/j.jns.2015.08.617

550

WFN15-0629

#### Miscellaneous Topics 1

### Vertebrobasilar pathology of acute isolated vertigo

B. Kim<sup>a</sup>, J. Ahn<sup>b</sup>. <sup>a</sup>Neurology, Eulji Hospital, Seoul, Korea; <sup>b</sup>Neurology, Seoul medical Center, Seoul, Korea

**Background:** Till now, several studies advocated the vascular etiology as a cause of acute isolated vertigo without relevant lesions on MRI. However, most of them were case series and, even in a few case-control studies, inclusion criteria were obscure and vascular risk factors were not considered.

**Objectives:** To investigate the clinical significance of vertebrobasilar artery (VBA) pathology in acute isolated vertigo without relevant lesions on MRI.

**Methods:** 84 patients (26 male, 59 female; 62.5 ± 10.2 years) with acute isolated vertigo who had no lesions on MRI were gathered. Seventy nine controls (30 male, 49 female; 58.4 ± 10.1 years) consisted of subjects with clinically definite BPPV, epilepsy, tension headache, or lacunar infarction. The vascular pathology of VBA and anterior circulation were examined and graded by the findings of MRA. Focal stenosis more than 50%, non- or faint-visualization, or dolichoectasia of VBA were regarded as significant. Risk factors of atherosclerosis were investigated and the severity of small vessel disease on MRI were ranked.

**Results:** Significant vascular pathology of VBA was found more frequently in patients with acute isolated vertigo (32.1%) than in controls (16.5%) ( $p < 0.05$ ). Significant vascular pathology of anterior circulation and SVD were not different, too ( $P > 0.05$ ). Multivariate analysis including all the possible variables investigated confirmed the significant correlation between VBA pathology and acute isolated vertigo in our subjects ( $p < 0.05$ ).

**Conclusion:** This study demonstrates that there is a significant correlation between VBA pathology and acute isolated vertigo without lesions on MRI. It can support the importance of VBA pathology as a cause of acute isolated vertigo.

doi:10.1016/j.jns.2015.08.618

551

WFN15-0074

#### Miscellaneous Topics 1

### Intracranial spreading of anaplastic astrocytoma in the spinal cord via cerebrospinal fluid pathway

C. Kim, J.H. Cheong, J.M. Kim. Neurosurgery, Hanyang University Guri Hospital, Guri Gyeonggido, Korea

**Background:** Intraspidal dissemination of intracranial tumor has been reported in several types of primary central nervous system neoplasms; however, Intraventricular dissemination of spinal cord glioma is rarely reported.

**Objective:** The authors report an unusual patient with intraventricular dissemination of anaplastic astrocytoma developed in the conus medullaris.

**Patient and methods:** A 53-year-old male presented with a gradual onset of pain and paresthetic numbness in the both legs. Neurologically, there were no significant deficits. Magnetic resonance images



(MRI) with gadolinium showed a 2.4 x 1.4 x 1.3 cm sized homogeneously well demarcated, intramedullary tumor in the conus medullaris.

**Results:** Osteoplastic laminotomy was undertaken to remove the tumor. Tumor was resected subtotally and pathologically confirmed as the anaplastic astrocytoma. The patient has been followed by cyberknife radiosurgery. Thirty-one months after his original presentation, he was referred with sudden onset of altered consciousness and respiratory difficulty. Brain computed tomography (CT) scans revealed an obstructive hydrocephalus and intraventricular tumor. He undertook external ventricular drainage and cared with ventilator. Cerebrospinal fluid examination demonstrated malignant tumor cells. His family refused further treatment and the patient was expired ultimately.

**Conclusions:** intracranial spreading of a primary intramedullary anaplastic astrocytoma is a rare occurrence. In this report we illustrated a patient with spinal cord anaplastic astrocytoma with delayed intraventricular dissemination. This report suggests that periodic intracranial observations should be required in the management of spinal cord tumors.

doi:10.1016/j.jns.2015.08.619

552

WFN15-0409

#### Miscellaneous Topics 1

##### Functional and morphological evaluations of blue light-emitting diode-induced retinal degeneration in mice

I. Kim<sup>a</sup>, G.H. Kim<sup>a</sup>, S.S. Paik<sup>a</sup>, H.I. Kim<sup>b</sup>, M.Y. Lee<sup>a</sup>, J. Kim<sup>a</sup>. <sup>a</sup>Department of Anatomy, The Catholic University of Korea, Seoul, Korea; <sup>b</sup>Retina, Gyeongju St. Mary's Eye Clinic, Gyeongju-si, Korea

Retinal degeneration (RD) is a general cause of blindness. To study its pathogenesis and evaluate the effects of new therapeutic agents for RD before clinical trials, it is essential to establish reliable and stable animal models. We investigated an RD model created by exposing mice to a blue light-emitting diode (LED), which induced photoreceptor cell death, and thus have introduced a new animal model. Electroretinographic recordings showed that both a- and b-waves were decreased in the retinas after blue LED exposure in an illuminance-dependent manner. Hematoxylin and eosin staining, terminal deoxynucleotidyl transferase dUTP nick end labeling assay, and electron microscopy showed massive photoreceptor cell death by apoptosis in the central region of the retina. Retinal stress and inflammation were detected by increased expression of glial fibrillary acidic protein and by electron microscopy findings demonstrating microglia infiltration in the outer nuclear layer and subretinal space. In addition, increased labeling of 8-hydroxy-2'-deoxyguanosine, a marker for oxidative stress, was observed in the retinas from blue LED exposure. These results suggest that blue LED-induced RD may be a useful animal model to study the pathogenesis of RD, including age-related macular degeneration, and to evaluate the effects of new therapeutic agents before clinical trials where oxidative stress and inflammation are the underlying RD mechanisms.

doi:10.1016/j.jns.2015.08.620

553

WFN15-0666

#### Miscellaneous Topics 1

##### Cerebellar transcranial magnetic stimulation (TMS) improves retina functional state in patients with diabetic retinopathy

N. Kresyun<sup>a</sup>, T. Muratova<sup>b</sup>, L. Godlevsky<sup>c</sup>. <sup>a</sup>Ophthalmology, Odessa National Medical University, Odessa, Ukraine; <sup>b</sup>Neurology, Odessa National Medical University, Odessa, Ukraine; <sup>c</sup>Biophysics Informatics and Medical Devices, Odessa National Medical University, Odessa, Ukraine

**Objective:** The characteristics of visual evoked potentials (VEP) have been studied in diabetic patients with and without diabetic retinopathy.

**Methods:** Magnetic impulses (2.0 TI at the height of impulse) have been delivered to the cerebellar surface transcranially using the "Neuro-MS/D", (Russia), and VEP have been registered every 20 s from the moment of photostress during one minute.

**Results:** An increase of the latency period and a reduction of the VEP amplitude have been recorded in the period following photostress exposure of the macular part of the retina. The VEP characteristics restored to the initial level in  $74.3 \pm 3.1$  s from the photostress moment in the control group; while in diabetic patients without and with retinopathy this index was  $86.5 \pm 5.5$  s and  $131.7 \pm 10.2$  s respectively. In the presence of cerebellar TMS (2.0 TI, 40 impulses) the VEP amplitude depression was less pronounced, and the restoration period of the VEP characteristics shortened to  $90.5 \pm 6.8$  s in patients with diabetic retinopathy.

**Conclusions:** Retinopathy development is linked to prolonged VEP latency period (P100), lowering of the N75-P100 amplitude, as well as to enlargement of the recovery period of the retina's functional capacity in patients suffering from the diabetes mellitus in the presence of photostress. Cerebellar TMS facilitates a faster recovery of the retina's functional capacity in response to photostress in diabetic patients with retinopathy. Periodical cerebellar TMS may be considered as a prevention method as well as a treatment method of diabetic retinopathy.

doi:10.1016/j.jns.2015.08.621

554

WFN15-1302

#### Miscellaneous Topics 1

##### Indirect carotid cavernous fistula type c: a case report

M. Laurentino<sup>a</sup>, C.O.M. Afonso<sup>a</sup>, T.A.F. Rocha<sup>b</sup>, J.J. Silva<sup>b</sup>, J.F.N. Melo<sup>b</sup>, M.E.T. Dourado<sup>a</sup>, C.O. Godeiro Junior<sup>a</sup>, P.S.M. Brito<sup>a</sup>, M.M. Figueiredo<sup>a</sup>, C.E.R. Correia<sup>a</sup>. <sup>a</sup>Neurology, HUOL, natal, Brazil; <sup>b</sup>Neurosurgery, HUOL, natal, Brazil

**Background:** Most Carotid-cavernous fistulas (CCF) are high-flow lesions, with a direct connection between the intracavernous carotid artery and the surrounding cavernous venous sinus, with abrupt and progressive symptoms (headache, vision impairment, ophthalmoplegia, orbital bruit and congestion), that occur usually after head trauma (type A in Barrow classification). Indirect low-flow CCF from dural branches of internal carotid artery (ICA) (Type B), external carotid artery (ECA) (Type C) or both (Type D) more often has spontaneous, insidious and incomplete clinical presentation. Cerebral angiography is the gold standard for the definitive diagnosis, classification, and planning of THE treatment for these lesions.

**Objective:** report a case of CCF Type C.

**Patients and Methods:** a 57 year old woman presented along a month with progressive right temporal headache, diplopia, conjunctival injection (red eye) and palpebral ptosis. Neurologic examination revealed proptosis and chemosis with slight limitation of eye movement, without audible bruit over the globe. Brain MRI showed right upper ophthalmic vein ectasia and discrete enlargement of right cavernous sinus. Cerebral Angiography confirmed right CCF arose from dural branches of ECA.

**Results:** Percutaneous transarterial CCF embolization was performed with total improvement of symptoms.

**Conclusion:** The indirect CCF is usually oligosymptomatic and it's hard to diagnoses. Indirect CCFs tend to occur more frequently in post-menopausal women, however it was a rare condition, mainly the type C fistula. The cause of these lesions is still obscure, but

infants presenting with dural fistulas in the literature furnish some evidence to congenital origin

doi:10.1016/j.jns.2015.08.622

555

WFN15-0382

#### Miscellaneous Topics 1

### Nras-mutated primary leptomeningeal melanomatosis in the era of targeted chemotherapy

M. Lim Fat<sup>a</sup>, C. Maurice<sup>b</sup>, R. Kiehl<sup>c</sup>, R. Wennberg<sup>d</sup>. <sup>a</sup>Neurology, University of Toronto, Toronto, Canada; <sup>b</sup>Neurology and Medical Oncology, Princess Margaret Hospital, Toronto, Canada; <sup>c</sup>Laboratory Medicine and Pathology, University Health Network, Toronto, Canada; <sup>d</sup>Neurology, University Health Network, Toronto, Canada

**Introduction:** Primary leptomeningeal melanomatosis is a rare melanocytic malignant tumor of the CNS for which molecular genetic studies can guide management.

**Case description:** A 28 year-old man with no significant past medical history presented to hospital with seizures, behavioral changes and drowsiness. He was afebrile and his initial physical examination showed grade II papilledema. He had normal bloodwork including a workup for inflammatory and infectious causes. CSF analysis showed lymphocytic pleocytosis but culture, cytology and flow cytometry were all negative. Brain MRI showed significant diffuse leptomeningeal enhancement. The patient's course progressed with worsening headaches, vomiting and the development of cranial nerve deficits. A brain biopsy was performed which revealed leptomeningeal melanomatosis with molecular studies negative for the BRAF mutation and positive for the NRAS mutation. Workup for systemic melanoma was negative. The patient was started on a combination of Carboplatin and Paclitaxel. Unfortunately, he continued to deteriorate despite chemotherapy and systemic steroids and was transferred to a palliative care unit 3 months after his presentation.

**Discussion:** This case illustrates the diagnostic and management challenges of primary CNS melanoma. Cases involving NRAS positive primary CNS melanoma have been described in children but remain exceedingly rare in adults. While BRAF-mutated tumors are treated with selective BRAF inhibitors, small molecules that target NRAS-mutated tumors are not currently available, and treatment usually focuses on the MAPK pathway. Further molecular research is needed to guide future treatment in adult patients with NRAS-mutated primary CNS melanoma.

doi:10.1016/j.jns.2015.08.623

556

WFN15-1239

#### Miscellaneous Topics 1

### Perception of sleep after a polysomnography in a sleep laboratory

D. Lira<sup>a</sup>, N. Custodio<sup>a</sup>, E. Bujaico<sup>b</sup>, L. Núñez del Prado<sup>c</sup>, S. Castro-Suárez<sup>c</sup>, R. Montesinos<sup>a</sup>, E. Herrera-Pérez<sup>a</sup>. <sup>a</sup>Lima, Instituto Peruano de Neurociencias, Lima, Peru; <sup>b</sup>Lima, Servicios Médicos de Diagnóstico, Lima, Peru; <sup>c</sup>Lima, Instituto Nacional de Ciencias Neurológicas, Lima, Peru

**Background:** Polysomnography is the gold standard for the diagnosis in sleep medicine, its realization included numerous electrodes and sensors on different body parts, which could hinder sleep.

**Objective:** Determine the perception of sleep in patients who made a polysomnography in a sleep laboratory in Lima. Peru.

**Patients and methods:** Patients who underwent polysomnography in a sleep laboratory, who completed an interview of satisfaction at the end of the test.

**Results:** 301 patients were evaluated, 196 were male (65,11%), with an average age of 46,82 years, with an average BMI of 28,54 kg / m<sup>2</sup>. The average time it took to sleep according to the reference of the patients was 33,20 minutes, 126 patients reported sleep same or even more so than at home (42,86%), of the patients who slept badly 30,12 attribute it to the sensors. They felt tired the next day 90 patients (29,90%), 61 patients reported having dreamed (20,26%), 182 patients awoke alone (60,46%) and 119 were awakened by the technologist (39,53%).

**Conclusion:** Polysomnography is a noninvasive diagnostic procedure that although requires the placement of a large number of sensors, not difficult to sleep according to the perception of patients that made a polysomnography.

doi:10.1016/j.jns.2015.08.624

557

WFN15-0322

#### Miscellaneous Topics 1

### Benign paroxysmal positional vertigo may be the most common cause of dizziness in emergency department

W.Y. Qiao<sup>a</sup>, J.G. Liu<sup>b</sup>, H. Zeng<sup>a</sup>, W.H. Jia<sup>c</sup>, B. Liu<sup>a</sup>, J. Tan<sup>d</sup>. <sup>a</sup>Emergency Center, Beijing Chaoyang Hospital (Jingxi Campus), Beijing, China; <sup>b</sup>Department of Neurology, Navy General Hospital, Beijing, China; <sup>c</sup>Department of Neurology, Beijing Chaoyang Hospital (Jingxi Campus), Beijing, China; <sup>d</sup>Otorhinolaryngological Department, Beijing Chaoyang Hospital (Jingxi Campus), Beijing, China

**Objective:** To explore the spectrum of the causes of the dizziness in Emergency Department and to improve the diagnosis efficiency and reduce the misdiagnosis.

**Methods:** With the help of Neurological and otorhinolaryngologic doctors, 1857 cases of dizziness in Emergency Department were enrolled and the etiological analysis was stratified by ages, sex.

**Results:** (1) The three top of diagnoses for these 1857 patients were respectively benign paroxysmal positional vertigo (BPPV, for 31.7%), Hypertension (24.0%), posterior circulation ischemia (PCI, for 21.0%). (2) Stratified by ages, all the patients were divided into 5 ages groups, and the three top of etiological factors were accordingly showed, as follows: BPPV (7 cases), migraine-associated vertigo (2 cases), unknown cause (1 case) for the group of <18 years; BPPV (51.5%), migraine-associated vertigo (14.5%), Neurosis (7.3%) for the group of 18 ~ 44 years; BPPV (36.8%), Hypertension (22.4%), migraine-associated vertigo (11.2%) for the group of 45 ~ 59 years; Hypertension (30.8%), PCI (29.8%), BPPV (22.9%) for the group of 60 ~ 74 years; PCI (30.7%), Hypertension (28.6%), BPPV (25.5%) for the group of 75 ~ 92 years.

**Conclusions:** (1) In Emergency Department, BPPV should be considered firstly when vertigo were triggered by positional change repeatedly, especially for young and middle-aged women, and in middle-aged patients, the other top of causes of dizziness are respectively migraine-associated vertigo, Neurosis, and Meniere's disease, especially in female (except for the latter). (2) Hypertension should be screened firstly in the middle-aged and elderly patients presenting mainly with heavy-head, stretching, et al. (3) Though the dizziness caused by PCI and the other cerebral vascular diseases may be more common in elderly patients, BPPV should not be ignored, since BPPV is second in constituent ratio to PCI and Hypertension.

doi:10.1016/j.jns.2015.08.625

558

WFN15-1224

**Miscellaneous Topics 1****The contralateral cortical silent period is not altered in primary restless legs syndrome / willis-ekbom disease**

S. Magalhães<sup>a</sup>, G. do Prado<sup>b</sup>, A. Eckel<sup>c</sup>, E. Amaro Jr.<sup>a</sup>, A. Conforto<sup>a</sup>.  
<sup>a</sup>Instituto do Cérebro, Hospital Israelita Albert Einstein, Sao Paulo, Brazil;  
<sup>b</sup>Neurosonno, Universidade Federal de São Paulo – UNIFESP, Sao Paulo, Brazil;  
<sup>c</sup>Departamento de Neurociências e Ciências do Comportamento, Hospital das Clínicas da Faculdade de Medicina (HCFRMP) USP de Ribeirão Preto, Sao Paulo, Brazil

**Background:** Restless legs syndrome (RLS) is characterized by unpleasant sensations and an irresistible urge to move the lower limbs. A reduction in duration of the cortical silent period (CSP) induced by transcranial magnetic stimulation, believed to reflect activity of GABA<sub>B</sub> neurons, has been inconsistently reported in RLS.

**Objectives:** 1) To compare the CSP duration, in patients with primary RLS and in healthy subjects; 2) To correlate these measures with severity of RLS symptoms.

**Patients and Methods:** Patients were grouped according to scores in the international RLS severity scale, IRLSS: (light/moderate [IRLSS < 20] = RLS<sub>LM</sub>; severe/very severe [IRLSS ≥ 20] = RLS<sub>SVS</sub>). Resting (rMT) and active (aMT) motor thresholds as well as CSP were measured. We obtained patient and Institutional Review Board (IRB) approval. Mann-Whitney tests were used to compare results in patients and in controls, and to compare results in patients with RLS<sub>LM</sub> and RLS<sub>SVS</sub>.

**Results:** Thirty one (25 F/6 M) patients with primary RLS and 13 healthy subjects were included. Twenty one patients had IRLSS ≥ 20 (RLS<sub>SVS</sub>) and 10, IRLSS < 20 (RLS<sub>LM</sub>). TMS results were (RLS x controls) were: rMT (69.2 ± 13.8% x 67.9 ± 13.2%; p = 0.78); aMT (54.6 ± 10.4% x 55.3 ± 12.6%; p = 0.88); CSP duration (108.7 ± 36.3 milliseconds(ms) x 106.1 ± 36.5 ms; p = 0.83). CSP duration was not significantly different between the two groups of patients with different severities of symptoms (RLS<sub>LM</sub> 112.3 ± 34.7 x RLS<sub>SVS</sub> 103.0 ± 37.9; p = 0.51).

**Conclusion:** These results do not support the hypothesis that GABA<sub>B</sub> neurons are relevant to RLS pathogenesis.

doi: 10.1016/j.jns.2015.08.626

559

WFN15-0493

**Miscellaneous Topics 1****Case series: acute bacterial meningitis (ABM) and stroke in newborns and infants**

R. Santibañez<sup>a</sup>, I. Huete<sup>b</sup>, J.P. Cruz<sup>b</sup>, M. Hernandez<sup>a</sup>. <sup>a</sup>Pediatrics, Universidad Catolica de Chile, Santiago, Chile; <sup>b</sup>Radiologia, Universidad Catolica de Chile, Santiago, Chile

Despite advances in treatment and intensive care, acute bacterial meningitis (ABM) continues to cause high rates of neurological sequelae.

**Objectives:** To describe clinical, neuroimaging and follow-up with 16 children with ABM-associated strokes.

**Patients and methods:** The pediatric stroke database of the Catholic University clinical hospital from January 2002 to December 2012 was reviewed and a follow-up was conducted.

**Results:** Seven newborns and nine infants were identified, nine of them male. Symptoms included fever associated with impairment of consciousness (13/16), seizures (12/16) and food intolerance (5/16), while none of the patients had focal deficits. B Streptococcus was

isolated in 6 and E Coli in one of the newborns. Pneumococcal and meningococcus were isolated respectively in 6 and 3 of the nine patients older than one month. The MRI showed cerebral arterial stroke in 15 cases (3 associated with cerebral venous thrombosis and 3 with arterial stenosis) and venous infarct in only one case. Thirteen of the 16 meningitis cases with cerebral infarcts were associated with poor outcomes. One patient died and eight developed cerebral palsy (6 quadriplegia and 2 hemiparesis). Ten cases had epileptic syndromes (4 refractory cases). Three cases had intellectual disabilities without motor disorders and 3 patients had severe sensorineural hearing loss, two of them with cochlear implants. Only 3 patients were without sequelae after 6-9 years of follow-up.

**Discussion:** Decreased mortality in ABM has not been associated with decreased neurological morbidity, probably as a result of cerebral infarction. It is necessary to know when and with which patients this complication occurs and the effect of early treatment and neuroimaging in the outcomes.

doi:10.1016/j.jns.2015.08.627

560

WFN15-0406

**Miscellaneous Topics 1****Psychiatric disturbances in frontal meningioma**

H.H.S. Matozinho<sup>a</sup>, L.C. Morais<sup>a</sup>, F.H.R. Silva<sup>a</sup>, V.C.J. Queiroz<sup>a</sup>, M.A. Bannach<sup>a</sup>, J.E.S. Cavalcante<sup>b</sup>, J.H.V. Pedroso<sup>a</sup>, R.B.R. Taveira<sup>a</sup>, P.L. Pedreira<sup>a</sup>, M.S. Cunha<sup>a</sup>. <sup>a</sup>Internal Medicine Department, Federal University of Goiás, Goiânia, Brazil; <sup>b</sup>Neurosurgery Department, Federal University of Goiás, Goiânia, Brazil

**Background:** Brain tumor patients have a tendency to suffer from psychiatric disturbances and, therefore, are often referred first to psychiatrists. One particular kind of benign tumors that might present exclusively as a progressive change of personality and intellect is the meningioma, especially the ones that compress the frontal lobes.

**Objective:** Highlight the relevance of both neurologic and psychiatric follow up for those patients with uncommon clinical features.

**Material and Methods:** A search was performed in Pubmed using "meningioma AND psychiatric". Only the free full texts published in the last 5 years were considered. There were 7 results, of which only 4 approached the subject of interest. 2 older studies were also considered.

**Results:** 80% of patients with psychiatric symptoms - cognitive changes, alteration of consciousness, personality/mood changes, anxiety, depression, schizophrenia - have frontal or limbic tumors. Frontal meningiomas should be investigated when a middle aged person, with no previous psychiatric history, develops a slowly progressive psychological change. Headache, papilledema, focal neurological signs may develop too, but only when the tumor has reached an advanced stage. It is well known that damages to the prefrontal cortex is highly associated with behavioral changes; and dorsolateral damages, with cognitive dysfunction - affecting memory, motor skills, spatial processing, attention, verbal fluency, concentration.

**Conclusion:** It is critical to highlight that psychological symptoms may also be the presentation of organic disease. Headache, personality changes, recent memory loss and relative lack of insight should warn about frontal meningioma and thus brain imaging plays an important role in the diagnosis.

doi:10.1016/j.jns.2015.08.628



561

WFN15-0458

**Miscellaneous Topics 1****Prognostic factors on surgical treatment for intramedullary tumors**

H.H.S. Matozinhos<sup>a</sup>, L.C. Morais<sup>a</sup>, V.C.J. Queiroz<sup>a</sup>, J.E.S. Cavalcante<sup>b</sup>, F.H.R. Silva<sup>a</sup>, M.G.P. Costa<sup>a</sup>, F.Y. Pereira<sup>a</sup>, L.C.P. Tavares<sup>a</sup>, G.M. Guimarães<sup>a</sup>. <sup>a</sup>Internal Medicine Department, Federal University of Goiás, Goiânia, Brazil; <sup>b</sup>Neurosurgery Department, Federal University of Goiás, Goiânia, Brazil

**Background:** Intramedullary tumors (IT) represent 2 – 4% of central nervous system tumors. Early diagnosis became possible and more precise thanks to lately advances in imaging techniques, which made the analysis of prognostic factors also crucial for the following steps, directly impacting the accuracy and effectiveness of treatment, as each patient may require different approaches.

**Objective:** Analyze main prognostic factors regarding surgical treatment of IT.

**Materials and methods:** A search was performed in Pubmed using “intramedullary tumors AND prognosis”. Only free full texts of the last 5 years were considered. There were 47 results, of which 4 approached more precisely the subject.

**Results:** Prognosis may be influenced by surgical manipulation when it causes edema, or interfere in spinal cord’s circulation. Another prognostic factor is tumor’s location in spinal cord, for the ones in thoracic level have poorer prognostic. There is great discussion regarding the importance of the type of tumor when deciding between partial/total surgical removal and morbidity and mortality. Whereas the Samii & Klekamp study of 1994 claims that it is not an important prognostic factor, the Houten & Weiner article of 2000 states that total removal would provide lower morbidity.

**Conclusion:** Throughout the analysis it was seen that age and gender did not seem to play an important role in IT prognosis, as it happens in other medical conditions. The focus of the prognostic factors relies on surgical manipulation, tumor location, both early diagnosis and treatment. Therefore, these variable factors are the main points to work on when dealing with IT.

doi:10.1016/j.jns.2015.08.629

562

WFN15-0461

**Miscellaneous Topics 1****Treatment and prognosis of glioblastoma multiforme: a literature review**

L.C. Morais<sup>a</sup>, V.C.J. Queiroz<sup>a</sup>, J.E.S. Cavalcante<sup>b</sup>, H.H.S. Matozinhos<sup>a</sup>, F.H.R. Silva<sup>a</sup>, M.G.P. Costa<sup>a</sup>, F.Y. Pereira<sup>a</sup>, L.C.P. Tavares<sup>a</sup>, G.M. Guimarães<sup>a</sup>. <sup>a</sup>Internal Medicine Department, Federal University of Goiás, Goiânia, Brazil; <sup>b</sup>Neurosurgery Department, Federal University of Goiás, Goiânia, Brazil

**Background:** Glioblastoma multiforme (GBM) is the most aggressive primary brain tumor, has extremely poor prognosis and high mortality even when all treatments available are performed.

**Objective:** Conduct a literature review focused on recent findings of treatment and prognosis of GBM.

**Material and methods:** A search was performed in Pubmed using “therapeutics AND glioblastoma AND child”. Only free full texts, related to humans and published in the last 5 years were considered. There were 12 results, of which 7 approached the subject of interest.

**Results:** Adeberg et al (2014) considered that advanced age (>60 years) and tumors located next to subventricular zones had reduced overall survival. Motomura et al (2011) demonstrated that IFN- $\beta$  enhances anticancer immune response and improve the Temozolomide chemosensitivity. Whereas Cohen et al (2011)

reported that there were no important therapeutic results in patients under chemoradiotherapy (Temozolomide) association, Soni (2014) found that it had slightly better therapeutic responses, although it was not statistically significant. Oike et al (2013) reported a higher median overall survival in patients under radiotherapy-Temozolomide treatment than in patients under exclusive radiotherapy. Seyfried et al (2010) claimed that ketonic diet, with low calorie intake, associated with drugs that interfere in glucose metabolism of neoplastic cells, was an alternative non-toxic treatment. Shimato et al (2013) indicated the possibility of restoring the function of GBM-related myeloid cells by blocking caveolin-1.

**Conclusion:** There is divergence among authors regarding GBM therapy, although Temozolomide has shown positive responses and new therapeutic possibilities are in development.

doi:10.1016/j.jns.2015.08.630

563

WFN15-0809

**Miscellaneous Topics 1****Ophthalmologic manifestations in multiple sclerosis: a literature review**

W.D. Oliveira<sup>a</sup>, L.M.O. Salviano<sup>a</sup>, J.J. Nassaralla Neto<sup>a</sup>, D.L.C. Isaac<sup>a</sup>, H.H.S. Matozinhos<sup>a</sup>, L.C. Morais<sup>a</sup>, J.E.S. Cavalcante<sup>b</sup>, A.P. Ramos<sup>b</sup>. <sup>a</sup>Internal Medicine Department, Federal University of Goiás, Goiânia, Brazil; <sup>b</sup>Neurosurgery Department, Federal University of Goiás, Goiânia, Brazil

**Background:** Multiple Sclerosis (MS) is an autoimmune condition, with chronic inflammation that destructs myelin, resulting in demyelination of the CNS and neurological impairment. MS affects mainly young adults (10-59 years); mostly women (2:1). It usually presents a relapsing-remitting phenotype. Ocular manifestations are commonly found in MS and may be the initial symptoms.

**Objective:** Review scientific literature of MS, focusing on the main ophthalmologic manifestations.

**Material and methods:** SciELO, PubMed, Bireme, Medscape were consulted using the following search combination “multiple sclerosis” AND “symptoms” AND “ocular manifestations”. Only the free full texts published in the last 15 years were considered. Only 7 approached the subject of interest.

**Results:** Inflammation and demyelization in MS may affect many aspects of the afferent and efferent visual pathways. Optic neuritis is the most common visual impairment and is the first manifestation in approximately 20% of patients; it usually results in eye pain, scotoma and visual field defects. Other important symptoms are the abnormalities of ocular motility, that may result in diplopia and internuclear ophthalmoplegia, which is very typical of this demyelinating condition. CN palsies (mainly CN VI palsies), intermediate uveitis, nystagmus and saccadic abnormalities can also be seen in MS.

**Conclusion:** Ophthalmology presents important role in diagnostic of MS and also the monitoring of patients with this disease because the presence of ocular symptoms in all the periods of MS is quite significant. It is important to highlight the variety of ophthalmologic manifestations, which are not limited to optic neuritis.

doi:10.1016/j.jns.2015.08.631

564

WFN15-0812

**Miscellaneous Topics 1****Meningioma case report with psychiatric presentation, evolving with thrombotic events**

R.B.F. Cavalcante<sup>a</sup>, H.H.S. Matozinhos<sup>b</sup>, M.A. Bannach<sup>b</sup>, L.C. Morais<sup>b</sup>, J.E.S. Cavalcante<sup>c</sup>, A.P. Ramos<sup>c</sup>, S.T.S.L. Leão<sup>a</sup>, F.S. Nazareno<sup>c</sup>, J.B.A. Juncos<sup>a</sup>.

<sup>a</sup>Neurosurgery Department, Santa Monica Hospital, Goiânia, Brazil;

<sup>b</sup>Internal Medicine Department, Federal University of Goiás, Goiânia, Brazil;

<sup>c</sup>Neurosurgery Department, Federal University of Goiás, Goiânia, Brazil

**Background:** Meningiomas are slow growing extra-axial tumors originated from arachnoid. Although they are usually benign, early diagnosis is difficult due to lack of clinical manifestations in the beginning of disease. Actually, sometimes the only symptom is psychiatric disorders.

**Objective:** Present and discuss a case from Santa Mônica Hospital, in Goiânia-GO, Brazil, of meningioma that also had thrombotic events.

**Patient and methods:** Man, 48 years, began with behavior changes and aggressivity in the past year and was diagnosed as a cognitive disorder and emotional lability, and medicated with risperidone. 40 days ago he was admitted to the neurosurgery service because of paraparesis, although some new symptoms had also appeared: visual acuity reduction, intermittent headache, anosmia. CT revealed voluminous meningioma in anterior fossa (6,3x6,2x2,8 cm) with midline shift, compressive effects of parenchyma and ventricular system. Emergency ventriculoperitoneal shunt was performed, and surgical tumor resection was postponed due to acute thrombosis of soleal, posterior tibial, fibular veins of both inferior limbs in post operative.

**Results:** It is largely known that compression of frontal lobes by meningiomas may have different presentations, including psychiatric just as it happened in this case. Another event that occurred in this case, and is frequently associated with cancer, was the deep vein thrombosis, which happens because of procoagulant factors synthesis by tumoral cells. Actually, neoplasms are one of the most important independent risk factors for thrombotic events.

**Conclusion:** There were two northern axes for this report: psychiatric manifestations for frontal meningiomas, and thrombotic events associated with tumours.

doi:10.1016/j.jns.2015.08.632

565

WFN15-1294

Miscellaneous Topics 1

Neuromyelitis optica diagnosis: a literature review

J.J. Nassaralla Neto<sup>a</sup>, L.M.O. Salviano<sup>a</sup>, W.D. Oliveira<sup>a</sup>, H.H.S. Matozinho<sup>a</sup>, L.C. Morais<sup>a</sup>, M.A. Bannach<sup>a</sup>, F.H.R. Silva<sup>a</sup>, J.E.S. Cavalcante<sup>b</sup>, A.P. Ramos<sup>b</sup>.

<sup>a</sup>Internal Medicine Department, Clinics Hospital Federal University of Goiás, Goiânia, Brazil; <sup>b</sup>Neurosurgery Department, Clinics Hospital Federal University of Goiás, Goiânia, Brazil

**Background:** Neuromyelitis optica (NMO), previously considered a clinical variant of multiple sclerosis (MS), is a demyelinating autoimmune inflammatory disorder that affects eyes and spinal cord, and is mainly characterized by an acute or sub-acute, recurrent optic neuritis, longitudinally extensive myelitis and hiccups/nausea.

**Objective:** Review the scientific literature and present the current knowledge on the diagnostic process and criteria of the condition.

**Material and methods:** This review is based on a selection performed in SciELO and PubMed, including articles, reviews and case / group studies in English, Spanish, Portuguese and Norwegian-languages.

**Results:** A main concern in the diagnosis of NMO is the differential issues with MS. With the discovery of aquaporin-4 (AQP4), specific autoantibody that is directly related to NMO pathophysiology, we can use a greater range of tools that lead to a more precise diagnosis. The diagnostic process is mainly clinical, laboratorial and neuroimaging in order to look for any autoimmune associated disorder. Liquor analysis, optical coherence tomography, electrophysiologic evaluation, and imaging findings sided by the search of antibodies against AQP4 are the main complementary exam methods. The existence of

seronegative NMO and overlapping in clinical and imaging findings with MS make this diagnosis a challenge.

**Conclusion:** Our understanding and knowledge about NMO is rapidly expanding since 1990, with the AQP4 findings. Although, great heterogeneity is still a challenge within this disease resulting in the increased relevance of further studies about NMO diagnosis and leading to a more clear and precise diagnostic.

doi:10.1016/j.jns.2015.08.633

568

WFN15-0119

Miscellaneous Topics 1

Localized overexpression of alpha-internexin within nodules in multinodular and vacuolating neuronal tumors

M. Nagaishi<sup>a</sup>, H. Yokoo<sup>b</sup>, S. Nobusawa<sup>b</sup>, Y. Fujii<sup>a</sup>, Y. Sugiura<sup>a</sup>, R. Suzuki<sup>a</sup>, Y. Tanaka<sup>a</sup>, K. Suzuki<sup>a</sup>, A.K.I.O. Hyodo<sup>a</sup>. <sup>a</sup>Neurosurgery, Dokkyo Medical University Koshigaya Hospital, Saitama, Japan; <sup>b</sup>Pathology, Gunma University Graduate School of Medicine, Gunma, Japan

**Background:** Multinodular and vacuolating neuronal tumors (MVNT) were recently referred to as a distinctive neuronal tumor, which histopathologically showed multiple tumor nodules, vacuolar alteration, and widespread immunolabeling for HuC/HuD.

**Patients and methods:** We report here a 22-year-old woman with MVNT with newly discovered immunohistochemical features.

**Results:** She presented with a 2 weeks history of continuous headache and underwent a subtotal removal of lesion in the left frontal lobe. Histopathology revealed well-defined multiple nodules composed of predominantly vacuolating tumor cells. The tumor cells revealed consistent immunolabeling for HuC/HuD and doublecortin, whereas immunostaining with NeuN was largely negative. In addition, extensive overexpression of alpha-internexin was obtained in the tumoral nodules, whereas immunostaining with neurofilament was negative. These immunohistopathology indicated that the tumor exhibited neuronal differentiation containing richly developed immature neuropil. She remained stable without a deterioration in her clinical symptoms or the lesion on MR imaging at 4 months after operation.

**Conclusion:** We showed the expression of several markers associated with neurogenesis in tumor cells and the presence of abundant neuropil expressing alpha-internexin in tumoral nodules in MVNT. These results supported that MVNT is a distinct histopathological entity.

doi:10.1016/j.jns.2015.08.634

569

WFN15-0148

Miscellaneous Topics 1

Convexity dural chondroma with expression of HMGA2

Y. Sugiura, M. Nagaishi, I. Takano, Y. Tanaka, K. Suzuki, A. Hyodo. Neurosurgery, Dokkyo Medical University Koshigaya Hospital, Saitama, Japan

**Background:** Chondromas are rare benign tumors that commonly originate from the base of the skull, while those arising from the dura mater are less common. Although the molecular mechanism underlying its pathogenesis remains largely unknown, 12q13-15 rearrangements followed by the activation of HMGA2, which is associated with cell proliferation, have been reported in soft tissue chondromas. A recent comprehensive analysis of mesenchymal tumors identified an *IDH1/2* mutation in cartilaginous tumors. However, these alterations have not yet been examined in dural chondromas.

**Patients and methods:** We here described clinical and these molecular features in a 45-year-old woman with convexity dural chondroma.

**Results:** She presented with a left-sided continuous headache. A 4.5-cm tumor was detected by MRI without a contrasting effect in the left parietal lobe and was totally removed. Histological examination revealed a cartilaginous structure including well-differentiated chondrocytes without the typical morphological features of meningioma, and the tumor was diagnosed as a chondroma. Molecular analysis demonstrated wild-type IDH1 and IDH2 and the expression of HMGA2.

**Conclusion:** We reported a new case of convexity dural chondroma with wild-type IDH1 and IDH2 and the expression of HMGA2. Our result suggested that the IDH1/2 mutation might be a characteristic feature in cartilaginous tumors from bone, but not soft tissue. In addition, the amplification of HMGA2 transcript may be associated with cell differentiation in meningeal chondromas.

doi:10.1016/j.jns.2015.08.635

570

WFN15-1285

#### Miscellaneous Topics 1

##### Behavioral improvement after sleep intervention for adolescents

Y. Oka<sup>a</sup>, F. Horiuchi<sup>b</sup>, K. Kawabe<sup>c</sup>. <sup>a</sup>Center for Sleep Medicine, Ehime University Hospital, Ehime, Japan; <sup>b</sup>Center for Child Health Behavior and Development, Ehime University Hospital, Ehime, Japan; <sup>c</sup>Department of Neuropsychiatry, Ehime University Graduate School of Medicine, Ehime, Japan

**Background:** Sleep impact on behavior and development especially during childhood and adolescence. Irregular sleep-wake schedule and excessive media exposure are prevalent among adolescents, and sleep intervention could impact not only on sleep habit but also on behavioral aspect.

**Objective:** The aim of our study was to identify the effect of sleep intervention targeting adolescents.

**Methods:** This study was conducted at Kuma Kogen town in Japan under the corporation of local education committee. Summer holiday workbook was developed for the intervention and was distributed to 204 junior high-school students. 171 students (83.1%) completed the workbook. Three educational sessions were created in the workbook: 1) self-management of sleep habits, 2) daytime light exposure and outside activity, and 3) self-control of media exposure before bedtime. Achievement of the goal on each topic was estimated and the behavioral outcome after the completion of intervention was identified.

**Results:** Achievement of the goal on each topics was reached in 72.6% for sleep wake schedule, 50.7% for optimal light exposure and 51.7% for appropriate media use. Improvement of sleep and daytime quality of life after the intervention was experienced in 56.5% of students; 24.5% of them are refreshed in the morning, 28.1% of them improved initiation of sleep and 45.6% of them are more active during daytime.

**Conclusions:** Sleep intervention using summer holiday workbook was effective both on the improvement of sleep habit and behavioral aspect.

doi:10.1016/j.jns.2015.08.636

571

WFN15-0302

#### Miscellaneous Topics 1

##### Nocturnal sleep-onset REM periods (nSOREMP) in adult patients evaluated at a sleep clinical setting

A. Oksenberg, V. Goizman, E. Eitan, K. Nasser, N. Gadoth. Sleep Disorders Unit, Loewenstein Hospital - Rehabilitation Center, Raanana, Israel

**Study Objectives:** To describe the clinical and polysomnographic characteristics of 59 patients without narcolepsy in whom nocturnal sleep-onset Rapid Eye Movements REM periods (nSOREMP) were recorded (the "study group") and to compare these data with that of 59 patients without nSOREMP ("the control group") matched for Age, BMI, Gender and Apnea Hypopnea Index (AHI).

**Design:** Retrospective analysis.

**Patients:** The clinical characteristics and polysomnographic (PSG) data of 2250 seeking treatment patients, who were studied at our Sleep Disorders Unit between January 2007 and August 2009, were screened for the presence of nSOREMP.

**Results:** Out of 2250 seeking treatment patients who underwent a complete PSG evaluation, 59 (2.6%) had nSOREMP. Compared to the control group, the patients with nSOREMP, had a lower sleep efficiency due mainly to a higher percentage of stage 1. They also showed more REM sleep periods and a higher percentage of REM sleep but a lower percentage of Slow Wave Sleep. The severity of sleep apnea and of periodic leg movements were not related to nSOREMP. The clinical and polysomnographic characteristics of this group did not differed from the rest of the study group.

A high percentage of REM sleep, low sleep efficiency and low percentage of SWS were significant predictors of nSOREMP.

**Conclusions:** In our large group of sleep disorders patients without narcolepsy, 2.6% had a SOREMP during nPSG. Their sleep showed mainly characteristics of REM propensity, possibly as a consequence of sleep deprivation / sleep fragmentation.

doi:10.1016/j.jns.2015.08.637

572

WFN15-0459

#### Miscellaneous Topics 1

##### Predictors of cerebrovascular causes in the emergency department patients with dizziness: application of the ABCD<sup>2</sup> and AB<sup>2</sup>D<sup>2</sup> scores

J. Park, H. Lee. Department of Neurology, Presbyterian Medical Center, Jeonju, Korea

Dizziness is a common presenting complaint in the emergency department (ED). Though most of them are caused by benign origins, identifying cerebrovascular causes is important. ABCD<sup>2</sup> score could be used as simply clinical prediction tool for assessing the cerebrovascular causes among patients with dizziness. But ABCD<sup>2</sup> score does not reflect the clinical symptoms of cerebrovascular dizziness. AB<sup>2</sup>D<sup>2</sup> score is modified from ABCD<sup>2</sup> score replaced with the clinical symptoms to balance with 2 points. We evaluated that AB<sup>2</sup>D<sup>2</sup> score would show significantly superior to identify cerebrovascular causes among ED patients with dizziness than ABCD<sup>2</sup> score.

We analyzed 302 patients presented with dizziness in ER, Presbyterian Medical Center for 5 months, prospectively. Patterns of dizziness, associated symptoms, past medical history, ABCD<sup>2</sup> score, AB<sup>2</sup>D<sup>2</sup> score, neuro-otologic examination, and final diagnosis were recorded.

Cerebrovascular causes of dizziness were found in 9.6% (29/302): 5 vertebro-basilar insufficiency, 15 cerebellar infarction, 6 cerebral infarction, 1 right MCA giant aneurysm, and 2 cerebellar hemorrhage. Patients with cerebrovascular causes had higher incidence of hypertension, diabetes mellitus, imbalance, abnormal neuro-otologic findings, higher ABCD<sup>2</sup> score and AB<sup>2</sup>D<sup>2</sup> score than other patients. ABCD<sup>2</sup> score of the area under the ROC curve (area under the ROC; AUC) was 0.813 (95% CI, 0.747-0.887), AB<sup>2</sup>D<sup>2</sup> score was 0.913 (95% CI, 0.858-0.969).

Higher ABCD<sup>2</sup> and AB<sup>2</sup>D<sup>2</sup> scores suggest cerebrovascular causes in patients with dizziness. AB<sup>2</sup>D<sup>2</sup> score is a simple and easily applied



tool and shows significantly superior than ABCD<sup>2</sup> scores for distinguishing cerebrovascular from non-cerebrovascular causes of dizziness in patients presenting to the ED.

doi:10.1016/j.jns.2015.08.638

573

WFN15-0292

#### Miscellaneous Topics 1

##### A study of clinical manifestation and therapies of 314 patients with psychogenic dizziness

X. Qi, Q. Dong, F.E.N.G. Qiu, Z. Wang, J. Liu. *Department of Neurology, Navy General Hospital of PLA, Beijing, China*

**Objective:** To summarize the clinical features and therapeutic methods in 314 cases with psychogenic dizziness in order to accumulate clinical experience and to conduct clinical work.

**Methods:** A total of 314 patients with psychogenic dizziness from neurology department of Navy General Hospital of PLA were enrolled in the study. Self-rating Anxiety Scale(SAS),Self-Rating Depression Scale (SDS) and Bech-Rafaelsen Mania Rating Scale(BRMS) were used for evaluation of mental status.

**Results:** Among all the cases were between ages 15 to 84 years (the average onset age 52 years) , 219 were female and 95 male. The patients' diagnoses were classified into 3 types according to different clinical features: anxiety and depression type( 260 cases, 82.8%), conversion disorder type (i.e., hysteria type: 29 cases, 9.2%) and mania type(25 cases, 8.0%). The drug increasing the concentration of excitatory transmitter (such as: Flupentixol and Melitracen Tablets) had a good therapeutic efficacy on anxiety and depression type. Alluding cure(10% Calcium gluconate Injection) had notable effect on hysteria type and mood stabilizer(such as: Sodium valproate Sustained-release Tablets) had notable effect on mania type.

**Conclusions:** Women tended to have psychogenic dizziness. It can be divided into three types: anxiety and depression type, conversion disorder type and mania type. Clinical features and auxiliary examinations of each type had their own characteristics, and treatment strategies were also different.

doi:10.1016/j.jns.2015.08.639

575

WFN15-1158

#### Miscellaneous Topics 1

##### Diagnosis of periodic limb movement disorder in a large tertiary referral centre in the United Kingdom using polysomnography: a review of practice

M.K. Robinson<sup>a</sup>, R. Kandler<sup>b</sup>, G. Dennis<sup>a</sup>, A. Ponnusamy<sup>b</sup>, C.A. Hewamadduma<sup>a</sup>. <sup>a</sup>*Department of Neurology, Royal Hallamshire Hospital, Sheffield, United Kingdom;* <sup>b</sup>*Department of Neurophysiology, Royal Hallamshire Hospital, Sheffield, United Kingdom*

**Introduction:** Periodic limb movement disorder (PLMD) is an important cause of disturbed sleep. Estimated prevalence is 4–11%, and it is linked to other respiratory and non-respiratory sleep disorders. Above 5 periodic limb movements of sleep (PLMS) per hour is defined as pathological, and described as a disorder if associated with arousals and excessive daytime somnolence. Diagnosis usually requires polysomnography (PSG).

**Method:** A retrospective study of 121 consecutive cases of suspected PLMD referred to the sleep clinic of a UK tertiary referral centre was

undertaken. Variables analysed include patient demographics, prior investigation, PSG results and outcomes.

**Results:** PLMD was diagnosed in 87% of all participants. 47% of the cases with PLMD had moderate to severe disease. PLMS occurred exclusively during NREM sleep in only 23% of patients, only during REM sleep in 2%, and during both stages of sleep in the remaining 75% of patients, contrary to previous evidence. Arousal rate was significantly higher in those diagnosed with PLMD; arousals were seen in 73%, compared with 27% of those without a diagnosis. Depression was the most frequent co-morbidity reported. Only 13% were hypoferritinaemic.

50% of pre-PSG diagnoses were either confirmed or refined. Management was initiated following PSG in 45%, and changed in 2%. Sleep quality was reported to have improved following management initiated after PSG in 25% of participants.

**Conclusion:** Although PSG was useful for ascertaining the correct diagnosis of PLMD, it did not improve sleep quality.

Patient and/or Institutional Review Board approval has been obtained for the above study.

doi: 10.1016/j.jns.2015.08.640

576

WFN15-1403

#### Miscellaneous Topics 1

##### The presence of sleep disorders and depression symptoms in high school students and pre-university courses

C. Rocha. *Pesquisa Avançada em Medicina do Sono HCFCMUSP, University of Sao Paulo School of Medicine, São Paulo, Brazil*

Adolescence sets in a troubled period is a transitional phase for many Brazilian adolescents, especially for those planning to entry in a public university.

**Objective:** This study aimed to verify the occurrence of symptoms of depression and sleep disorders among high school students and college preparatory courses.

**Material and method:** A cross-sectional, descriptive study was conducted.

**Results:** The analysis of the data indicates the occurrence of depressive symptoms and sleep disturbances. There was an association between the standard and quality of sleep and depression symptoms. The latency of 16–30 minutes of sleep, sleep participants on average 6 to 7 hours a night, use of drugs to get to sleep, malaise and show lack of enthusiasm for carrying out daily activities.

**Conclusion:** In view of these results, it is necessary that parents and professionals in the fields of health and education, be attentive to the presence of symptoms of depression and sleep disorders in adolescents.

**Keywords:** High school students. Depressive symptoms. Sleep disorders.

doi:10.1016/j.jns.2015.08.641

577

WFN15-1506

#### Miscellaneous Topics 1

##### Neuropsychology assessment device for awake neurosurgery

O. Samokhvalova<sup>a</sup>, S. Ostry<sup>b</sup>, A. Pulkrabkova<sup>c</sup>. <sup>a</sup>*National IT system of mental health and brain monitoring, Prague Psychiatric Centre, Prague, Czech Republic;* <sup>b</sup>*Department of Neurology, Ceske Budejovice Hospital, Ceske Budejovice, Czech Republic;* <sup>c</sup>*Department of Psychology, Military University Hospital Prague, Prague, Czech Republic*

Intraoperative neuropsychological assessment has become critical for neurosurgery awake operation. For **intraoperative brain**

**mapping neurosurgeon/neurologist performs the neuropsychological assessment of speech/visual/reading/executive etc. function during direct electrostimulation (DES) of brain area around the tumor.** An extended removal of diffuse low-grade glioma according to functional boundaries significantly increased progression free survival by delaying malignant transformation.

Based on neuropsychological protocol using for intraoperative language mapping, pre- and postoperative cognitive function evaluation at the departments of neurosurgery novel iPad based device has been developed. It allows individualized intraoperative assessment of different cognitive domain as well as precise evaluation of language deficits for further postoperative language rehabilitation. Algorithm enables real time analyzing of language deficits during DES, includes data of preoperative evaluation, structured set for intraoperative conversation and postoperative evaluation. Neuropsychological data could be synchronized with MRI navigation data, precise timing of language delay/arrest during DES permit better understanding of language organization.

Currently, advances in intraoperative brain mapping techniques results in a decrease of postoperative neurological and neuropsychological deficits. This could increase of progression free survival with preservation of good quality of life comparing to both incomplete, or anatomic landmark based resection. Computerized individually tailored intraoperative neuropsychological assessment could be the next step toward personalized “functional surgical neuro-oncology”.

doi:10.1016/j.jns.2015.08.642

578

WFN15-1565

#### Miscellaneous Topics 1

##### Search for sleep disorders in outpatient psychiatric practice

J. Santin<sup>a</sup>, E. Quintanilla<sup>b</sup>, J.O.S.E. Ivelic<sup>c</sup>. <sup>a</sup>Neurology, Pontificia Universidad Catolica de Chile, Santiago, Chile; <sup>b</sup>Sleep Medicine Center, Pontificia Universidad Catolica de Chile, Santiago, Chile; <sup>c</sup>Psychiatry, Pontificia Universidad Catolica de Chile, Santiago, Chile

**Introduction:** Psychiatric diagnosis is based on clinical grounds in the vast majority of cases. In this setting, comorbidities are frequent and in some cases can explain refractoriness to multiple therapeutic schemes. One common comorbidity are sleep disorders, often underdiagnosed and sometimes triggered or worsened by psychiatric treatment.

**Objective:** To evaluate in outpatient psychiatric practice the systematic search for common sleep disorders as comorbidity.

**Methodology:** Descriptive prospective cross sectional study. Participants psychiatrists answered an anonymous web based survey regarding how often they asked about sleep related breathing disorders, sleep habits, sleep schedules, hypersomnolence, stimulants use, parasomnias and sleep related movement disorders.

**Participants:** Clinical psychiatrists working at two outpatient clinics (UC-Christus Health System and Gesam Psychiatry Network).

**Results:** Of 165 surveys sent there were 74 responders (44.8%), 41 men and 33 women, with an average of 42 years of age. There was no significant difference in the percentage of answers or the frequency of items searched by both sexes, neither differences determined by physician's age. The analysis by diagnostic categories shows that the most explored ones were non-specific daytime sleepiness (83.7%), sleep schedules (70.2%) and sleep habits (>50%), while the least explored were the respiratory sleep disorders (<30%) and sleep-related movement disorders (17.5%).

**Conclusions:** The results show that among clinical psychiatrists, there is a significant proportion which does not search systematically for relevant sleep disorders, like sleep related breathing disorders,

sleep related movement disorders, probably due to low clinical suspicion. This highlights the need for systematic training in sleep medicine in psychiatry, given the significant clinical impact that sleep disorders can have psychiatric patients.

doi:10.1016/j.jns.2015.08.643

579

WFN15-1355

#### Miscellaneous Topics 1

##### Does gamma knife improve sleep quality of patients with hypothalamic hamartoma?

M.M. Sarr<sup>a</sup>, L.B. Seck<sup>b</sup>, A.D. Sow<sup>b</sup>, M. Ndiaye<sup>b</sup>, G. Daquin<sup>c</sup>, M.M. Ka<sup>a</sup>, A.G. Diop<sup>b</sup>, M.M. Ndiaye<sup>b</sup>, J. Regis<sup>d</sup>. <sup>a</sup>Medecine and medical specialties, UFR Santé, Thiès, Senegal; <sup>b</sup>Clinique neurologique, UCAD, Dakar, Senegal; <sup>c</sup>Département EEG, Centre Saint Paul, Marseille, France; <sup>d</sup>Neurochirurgie stéréotaxique et fonctionnelle, Hopital Timone, Marseille, France

**Background:** Hypothalamic hamartomas are pseudotumoral heterotopic formations. They can be asymptomatic or result in various events such precocious puberty, drug-resistant epilepsy and sleep disorders. Management may fall within conventional surgery or gamma knife. Our objective is to evaluate gamma knife contribution in sleep of patients with hypothalamic hamartoma.

**Patients and methods:** 19 patients completed a sleep questionnaire before and after gamma knife intervention. The questionnaire is called Pittsburgh sleep quality index (PSQI). It consists of 19 items to give a score sleep between 0 and 21 and thus to compare the scores before and after gamma knife. A subsidiary question allowed patient to appreciate himself the quality of his sleep.

**Results:** Our results showed that PSQI score was improved in 52.63% of cases, deteriorated in 21.05% of cases and unchanged in 21.05% of cases. For subsidiary question, 14 patients (73.68% of cases) found the quality of their sleep at least "enough good" after gamma knife intervention. 2 patients had found their sleep without change. Finally, no "bad" or "very bad" items were reported.

**Conclusion:** Sleep evaluation by PSQI and subsidiary question appreciation show that the gamma knife substantially improves sleep quality of patients with hypothalamic hamartoma.

**Keywords:** Hypothalamic hamartoma, Sleep, Evaluation, Gamma knife, Pittsburgh

doi:10.1016/j.jns.2015.08.644

580

WFN15-0575

#### Miscellaneous Topics 1

##### Overlap syndrome: Ohtahara and west, secondary to hemimegalencephaly

B.C. Rodrigues do Amaral, V. Amorim, E.S. Siqueira, C.V. Castro, L. Seguti Ferreira. *Pediatria, University of Brasília, Brasília, Brazil*

**Background and Objective:** The Hemimegalencephaly is a major but rare hamartomatous congenital malformation of the brain, involving excessive growth limited to one cerebral hemisphere. It has been one of the most enigmatic of the many cerebral malformations, because this asymmetric dysgnesis cannot be identified as a disturbance or maturational arrest in any normal stage of development. We present a case report of a patient with hemimegalencephaly. The patient presented tonic seizures (Ohtahara syndrome) and infantile spasms (West syndrome) and asymmetric suppression-burst pattern EEG.

**Case report:** GJML, 2 months, male, born 39 weeks, without complications in the perinatal period. When he was 1 month old, the first seizure was observed, with gaze deviation up and clonic movements of the limbs. He had clonic seizures and tonic seizures, daily. Twenty days later, the patient began infantile spasms in flexion. Physical examination revealed macrocephalia, ipsilateral hemifacial hypertrophy with a mass in lower half of left cheek (lipoma), and skin lesion in cervical region, cervical hypotonia and pyramidal signs. The neuroimaging showed gross asymmetry with enlargement of one hemisphere, dysplastic cortex, and asymmetry and deformity of the ventricular system. The EEG showed asymmetric suppression-burst pattern.

**Conclusion:** The authors report a rare case of a hemimegalencephaly with some peculiarities. An early asymmetric suppression-burst may be observed in newborns and young infants with the clinical picture of Ohtahara syndrome in only 5 % of the patients. In the clinical case described, also there was observed a overlap syndrome between Ohtahara-West.

doi:10.1016/j.jns.2015.08.645

581

WFN15-0300

Miscellaneous Topics 1

**Characterizing sleep disorders and disturbances in children and youth: age makes a difference**

P. Seibert, M. Mooney, J. Martin. *Research Institute, Saint Alphonsus Regional Medical Center, Boise, USA*

Sleep disorder (SD) symptomatology is age-specific. Indeed, children with SDs may display symptoms characteristic of attention-deficit/hyperactivity disorder (ADHD), such as inattentiveness, hyperactivity, and aggressive behaviors, which can result in unnecessary medications, exacerbating the underlying SD. Recognizing that normal sleep is vital to somatic growth and neurological development, we designed this project to elucidate the complex covariance of sleep with overall health specific to children/youth.

We constructed a 111-item questionnaire and a 12 item questionnaire specific to pediatrics to use in conjunction with nocturnal polysomnography (NP), multiple sleep latency tests (MSLT), the Epworth Sleepiness Scale (ESS), and medical chart reviews of people referred to our institution for SD evaluation. We analyzed these data to create a characterization specific to children/youth (N = 57; age 1-16; mean 9.28; 36 male, 21 female). We then compared this with data from an adult sample (N = 729).

Comparative analyses revealed myriad similarities and differences: for example, proportionally, children/youth were more likely to present with CNS/facial abnormalities diagnoses, ADHD, spending more time in N3, breathing with mouth open, and sleepwalking, while adults were more likely to snore, be apneic, spend more time in N1, and REM sleep. Both groups complained of body pain, headaches, concentration problems, anxiety, and had abnormal sleep architecture.

Our sample suggests that pediatric cases are more likely to be referred for professional sleep studies when other significant medical issues are present. Although we found some similarities when comparing adults and pediatrics, we found opposing patterns, emphasizing the critical need to explore age-specific characteristics in SDs.

doi:10.1016/j.jns.2015.08.646

582

WFN15-0562

Miscellaneous Topics 1

**The importance of neurological evaluation in school failure in a cohort of Brazilian children**

S.R.M.A. Gatto, E.S. Siqueira, T.A.C. Martins, L. Seguti. *Pediatrics, University of Brasilia, Brasilia, Brazil*

**Background:** According to UNESCO data, Brazil occupies the 16th position of school failure in the world, with an estimated incidence of 21%. The association of school failure and neurological disorders seems to be underestimated.

**Objective:** The objective of this study is to evaluate the impact of prenatal pathological events and abnormal neurological evaluation in children with a history of school failure.

**Materials and methods:** We performed a prospective analysis of 141 children from the 3rd to 5th grade of a public school in Brasilia, Brazil. 70 children never repeated a grade and 71 repeated a grade less than three times. Prenatal history data was recorded and children were evaluated with a complete neurological examination and assessment of their skills in reading, writing and logical thinking. Chi-square test was used to assess the difference between the two groups and the variables were found to be significant when  $p < 0.05$ . Informed consent was obtained from the parents.

**Results:** Prenatal pathological events were detected in 33.8% of the children who experienced a school failure and only in 22.8% in the control group. 63.7% of children with a history of school failure had a neurological disorder, versus 14.3% in the control group ( $p = 0,000$ ). Among the neurological diagnosis, there were children with language disorder, intellectual disability, autism spectrum disorder and attention deficit/hyperactivity disorder.

**Conclusion:** We found an association between abnormal neurological evaluation and school failure. This finding points to the importance of early diagnosis of neurological disorders in order to avoid impact on school performance.

doi:10.1016/j.jns.2015.08.647

583

WFN15-0565

Miscellaneous Topics 1

**The influence of social factors in learning problems in a cohort of Brazilian children**

S.R.M.A. Gatto, E.S. Siqueira, T.A.C. Martins, L. Seguti. *Pediatrics, University of Brasilia, Brasilia, Brazil*

**Background:** Learning problems comprehend difficulties secondary to inadequate pedagogical approach, familiar and social issues.

**Objective:** The objective of this study is to describe the influence of social factors in children with a history of school failure.

**Methods:** We evaluated 141 children from a public school in Brasilia, Brazil. 70 children had adequate school performance and 71 experienced school failure. The following variables were studied: parental education level and marital status, parental illicit drug use and alcoholism, parental employment and salary. Chi-square test was used to assess the difference between the two groups and the variables were found to be significant when  $p < 0.05$ . Informed consent was obtained from the parents.

**Results:** The following results were found in the group of children with a history of school failure and in the control group, respectively: father's illicit drug use 4.2% versus 4.3%; mother's illicit drug use 2.8% versus 1.4%; paternal alcoholism 47.9% versus 5.7%; maternal alcoholism 2.8% versus 4.3%; father's unemployment in 8.1% versus 1.6%; mother's unemployment 2.8% versus 7.1%; married parents in



57.5% versus 55.7% and mean salary R\$481,45 versus R\$401,7. The only factor with statistical significance was a history of paternal alcoholism (47.9% in children with a history of school failure and 5.7% in the control group, with a  $p = 0,000$ ).

**Conclusion:** Paternal alcoholism had a negative influence on their children school performance, secondary to family disorganization. The lack of other risk factors is probably due to the similarity between the two groups, since they studied and lived in the same region.

doi:10.1016/j.jns.2015.08.648

585

WFN15-1367

#### Miscellaneous Topics 1

##### Zolpidem and the risk of suicide: a nationwide population-based case-control study

Y. Sun<sup>a</sup>, C.J. Lu<sup>a</sup>, C.C. Lin<sup>b</sup>, C.Y. Hsu<sup>c</sup>, C.H. Kao<sup>d</sup>. <sup>a</sup>Neurology, En Chu Kong Hospital, New Taipei City, Taiwan; <sup>b</sup>Management Office for Health Data, China Medical University, Taichung, Taiwan; <sup>c</sup>Graduate Institute of Clinical Medical Science, China Medical University, Taichung, Taiwan; <sup>d</sup>Nuclear Medicine and PET Center, China Medical University, Taichung, Taiwan

**Background:** Although suicide attempts have been listed in the warning statement for zolpidem, whether exposure to zolpidem is associated with an increased risk of suicide has not been confirmed.

**Methods:** In this nationwide case control study, the case group comprised 2199 people who committed suicide between January 1, 2002, and December 31, 2011. To create a control group, we randomly selected 10 patients matched to each case according to age, sex, urbanization and occupation. We measured the risk of suicide associated with zolpidem exposure by using adjusted odds ratios (ORs) and assessed the dose-response effect of zolpidem.

**Results:** After adjustment for potential confounders such as the comorbidities of schizophrenia, major depression, bipolar disorder, anxiety, insomnia, and other mental disorders; the Charlson comorbidity index (CCI); and combined use of zolpidem and benzodiazepine or antidepressants, zolpidem exposure significantly increased the risk of suicide with OR 2.06 (95% CI 1.82–2.34). The risk increased with the level of zolpidem use (ORs of 1.90, 1.98, and 2.73 for cumulative defined daily doses of <90, 90–179, and  $\geq 180$  mg, respectively;  $p$  for trend <0.0001). Subgroup analyses showed the exposure to zolpidem consistently increased OR for suicide in different groups of age, sex, urbanization level, occupation, mental disorders, CCI levels, and in groups of people with or without the presence of insomnia.

**Conclusions:** This study demonstrated a significantly increased risk of suicide in people using zolpidem. More aggressive protective measure on zolpidem prescription should be warranted to decrease the suicide rate and mortality.

doi:10.1016/j.jns.2015.08.649

586

WFN15-0266

#### Miscellaneous Topics 1

##### Insulinoma mimicking rapid eye movement sleep behavior disorder

K. Suzuki<sup>a</sup>, A. Kawasaki<sup>a</sup>, M. Miyamoto<sup>b</sup>, T. Miyamoto<sup>c</sup>, T. Kanbayashi<sup>d</sup>, M. Sato<sup>d</sup>, T. Shimizu<sup>d</sup>, K. Hirata<sup>a</sup>. <sup>a</sup>Department of Neurology, Dokkyo Medical University, Tochigi, Japan; <sup>b</sup>School of Nursing, Dokkyo Medical University, Tochigi, Japan; <sup>c</sup>Department of Neurology, Dokkyo Medical University Koshigaya Hospital, Saitama, Japan; <sup>d</sup>Department of Neuropsychiatry, Akita University School of Medicine, Akita, Japan

**Background:** Insulinoma is a rare endocrine tumor, manifesting various symptoms including nocturnal abnormal behavior.

**Objective:** We report 3 patients with insulinoma who presented with abnormal nocturnal behavior and injury during sleep, which simulated rapid eye movement sleep behavior disorder (RBD).

**Methods:** Between April 2004 and March 2014, 3 insulinoma patients whose nocturnal abnormal behaviors suggested RBD were identified. All the patients underwent polysomnography. Informed consent was obtained from all patients for being included in the study.

**Results:** In case 1, fasting glucose was 15 mg/dL with increased levels of insulin (15 $\mu$ U/mL), and in case 2 when the patient was transferred to the hospital due to disturbance of consciousness, hypoglycemia (29 mg/dl) was detected. In contrast, in case 3, fasting glucose sampling did not show hypoglycemia, but continuous glucose monitoring revealed nocturnal hypoglycemia. Mean period from initial symptoms to diagnosis of insulinoma was 7 months to 2 years. All 3 patients received anti-epileptic drugs previously with suspicion of epilepsy, but they were ineffective. Polysomnography showed no evidence of REM sleep without atonia in 3 patients. No patient remembered the event during sleep.

**Conclusion:** When a patient manifests abnormal behavior during the night and early morning, glucose monitoring is needed especially during the period from night to early morning. Clinicians should be aware that, although a rare disease, insulinoma can mimic parasomnia, such as RBD.

doi:10.1016/j.jns.2015.08.650

587

WFN15-0964

#### Miscellaneous Topics 1

##### Metastatic lesions mimicking bilateral ACA infarction leading to diagnosis of adrenal tumour: a case report

A. Cetiz<sup>a</sup>, H. Akgun<sup>a</sup>, S. Alay<sup>a</sup>, S. Tasdemir<sup>b</sup>, S. Hamcan<sup>c</sup>, O. Oz<sup>a</sup>, U. Ulas<sup>a</sup>, S. Demirkaya<sup>a</sup>. <sup>a</sup>Department of Neurology, Gulhane Military Medical Academy, ANKARA, Turkey; <sup>b</sup>Department of Neurology, Beytepe Military Hospital, ANKARA, Turkey; <sup>c</sup>Department of Radiology, Gulhane Military Medical Academy, ANKARA, Turkey

**Background:** Metastases are most commonly seen in the peritoneum, liver, lung, and bone, but they can be rarely seen in the brain.

**Objective:** In this case report, we present intracranial metastasis of an adrenal tumor mimicking a bilaterally anterior cerebral artery (ACA) occlusion.

**Patient and methods:** A 74-year-old female presented with complaints of inability to walk, amnesia, exhibiting strange behavior, and urine and feces incontinence. It was stated that the patient's symptoms began suddenly 1 week ago. Her neurological examination revealed that her state of consciousness was clear and cooperative, but location and time perception was damaged. The patient was paraparetic, fecal and urinary incontinence was present, and the patient suffered from decreased vision in the left eye. Bottom plantar responses were bilaterally flexor. Diffusion weighted MRI of the brain showed diffusion restriction in the bilateral ACA territory consistent with subacute ischemic stroke. Bitemporal slow wave activity was observed via electroencephalography. Echocardiography revealed a globally hypokinetic left ventricle. No significant stenosis was observed in the carotid-vertebral Doppler ultrasonography evaluation. Head and neck CT angiography were taken for further evaluation. ACAs were considered patent bilaterally.

**Results:** The follow-up brain MRI and MR spectroscopy revealed an enlargement consistent with a metastatic lesion. In evaluations to identify the primary focus, an abdominal CT scan revealed a right

adrenal tumor. The patient was diagnosed with brain metastasis due to adrenal tumor.

**Conclusion:** Intracranial masses can mimic ischemic events. Usually, these masses do not fit in vascular territories, but sometimes they coincide with vascular areas. Therefore, physicians should consider mass lesions in the differential diagnosis of ischemic stroke. Additionally physicians should keep in mind that these lesions may lead to primary tumors undiagnosed previously.

doi:10.1016/j.jns.2015.08.651

588

WFN15-0368

#### Miscellaneous Topics 1

##### A case report; mumps acute cerebellitis presented as hydrocephalus and brainstem compression

Meltem Uzun<sup>a</sup>, Yelda Çufalı<sup>b</sup>, Feride Kırıştıoğlu<sup>b</sup>, Muhittin Bodur<sup>c</sup>.  
<sup>a</sup>Dörtçelik Children Hospital, Pediatric Neurology; <sup>b</sup>Dörtçelik Children Hospital, Pediatric Intensive Care; <sup>c</sup>Uludağ University Hospital, Pediatric Neurology

E-mail address: meltempirti@yahoo.com (Meltem Uzun)

Presenter: Dr. Meltem Uzun

Acute cerebellitis, a condition that is frequent in early childhood, may result from viral or autoimmune aetiologies. Mumps is one of infectious pathogens but hydrocephalus and brain edema are rare.

An 9-year-old boy presented with occipital headache, vomiting. In the admission no findings on examination, there was no finding on cranial tomography. But in the second day he had a truncal ataxia, mild dysmetria and eye movement disorder. Her funduscopy results in papilloedema. Laboratory tests indicated mild leukocytosis and neutrophilia and the others are normal. A magnetic resonance image of the brain showed hydrocephalus with bilateral cerebellar swelling with brainstem compression. Serological investigation of mumps was positive. After treatment with steroids, diuretics the patient improved dramatically within 5 days. Repeated magnetic resonance imaging revealed a regression of the cerebellar edema.

Although acute cerebellitis is usually benign and self-limiting hydrocephalus was previously reported as a complication of acute cerebellitis. Magnetic resonance imaging is the modality of choice for the detection of inflammatory disorders of the cerebellum even in the lack of clinical symptoms of brain edema.

In conclusion, the acute hydrocephalus and tonsillar herniation associated with acute cerebellitis may be life-threatening, and warrants early diagnosis.

**Keywords:** Mumps, cerebellitis, hydrocephalus

doi:10.1016/j.jns.2015.08.652

589

WFN15-0387

#### Miscellaneous Topics 1

##### A case report: cerebellar ataxia associated to parvovirus b19

M. uzun<sup>a</sup>, M. bostanlı<sup>b</sup>, E. yıldırım<sup>c</sup>. <sup>a</sup>Child neurology, Dortçelik Child Hospital, Bursa, Turkey; <sup>b</sup>Pediatric Department, Dortçelik Child hospital, BURSA, Turkey; <sup>c</sup>Chairman of hospital, Dortçelik Child Hospital, BURSA, Turkey

Human parvovirus B19 (PVB19) is well known to cause erythema infectiosum and has other pathological manifestations such as central nervous system (CNS) diseases, aplastic crisis, thrombocytopenia, purpura, myocarditis, and arthritis. Meningitis and encephalitis have

been reported in association with this viral infection, but acute cerebellar ataxia has rarely previously been documented.

We report a 2 year old boy admitted acute cerebellar ataxia in association with erythematous skin lesion. He was diagnosed as human parvovirus B19 after serological tests. In his physical examination we remarked ataxic gait, nystagmus and erythematous lesions on body. In the 3rd day, idiopathic thrombocytopenic purpura was developed. All laboratory findings were normal except thrombocytopenia. He had normal cranial MR imaging. Serology was positive for antibodies to IgM and IgG antibodies against PVB19 in blood and cerebrospinal fluid. Ataxia and nystagmus disappeared in a week without any specific treatment.

Acute cerebellar ataxia occurs in association with various viral and non-viral infections and vaccines. It has been assumed that most acute cerebellar ataxia cases result from postinfectious allergic autoimmune reactions. Antineuronal antibodies were detected in patients following infections. Our case was thought to be acute cerebellar ataxia caused by PVB19 infection.

To the best of our knowledge, case reports of acute cerebellar ataxia associated with PVB19 infection are rare. Further attempts are required to clarify the role of this virus in the development of acute cerebellar ataxia as about 30% of PVB19 infections in children.

**Keywords:** acute cerebellar ataxia; erythema infectiosum; human parvovirus B19

doi:10.1016/j.jns.2015.08.653

590

WFN15-0796

#### Miscellaneous Topics 1

##### Subjective assessment of the presence of reverie and some features of emotional phenomena in the dreams of pregnant women

S.M. Valiensi<sup>a</sup>, F. Martin<sup>a</sup>, E. Cristiano<sup>a</sup>, G. Izbizky<sup>b</sup>. <sup>a</sup>Neurologia, Hospital Italiano, Capital Federal, Argentina; <sup>b</sup>Obstetricia, Hospital Italiano, Capital Federal, Argentina

Dream activity has sensory components, vegetative, emotional and delusion mainly during the REM (rapid eye movement) that would be linked to the dream activity. During pregnancy women are often more sensitive to changes and sleep is more fragmented.

**Objective:** In this study we analyzed and compared the emotional content of dreams along the 3 trimesters (G).

An observational cross-sectional study was conducted between August 2013 and June 2014. The Gruen's Scale in Spanish of subjective assessment of the subjective impression of the dreams, to quantitatively assess the type, number, frequency and intensity of the emotions of dreams. The differences between the average values obtained in each group were evaluated by statistical test ANOVA and "t" student. The study was approved by the Ethics Committee.

320 full scale for analysis were obtained. 30-39: 59%. Work: 77%. Casting: 60.3%. G2: 47.9% said they remember their dreams versus 45.3 in the G3 (p = 0.81). Vivid dreams: average 25.5. DS: 23.5 (p: 0.25)

The results showed that pregnant women have no more dream activity in a specific quarter. In the G2 47,9% stated remember their dreams versus 45.3 in the G3, where supposedly sleep is more fractionated by natural causes (p = 0.81) Unpleasant to pleasant dreams were discretely higher in G2 with 30.9% versus 29.1 in the G3. Our results allow us to refer to unpleasant dreams were discretely higher in G2 with 30.9% versus 29.1 in the G3 but found that our women are more pleasant than unpleasant dreams.

However, further studies are needed to corroborate our results.

doi:10.1016/j.jns.2015.08.654

591

WFN15-1380

**Miscellaneous Topics 1****RNF135, a ring finger protein, promote proliferation of human glioblastoma cells in vivo and in vitro via ERK pathway**Y. Xu, Y. Liu. *Neurosurgery, First Affiliated Hospital Dalian Medical University, Dalian, China*

**Background:** Ring Finger protein 135 (RNF135), located on 17q11.2, is a RING domain containing E3 ubiquitin ligase and functioned as the E3 ubiquitin ligase.

**Objective:** The aim of this study was to investigate the expression and function of RNF135 in human glioblastoma.

**Material and methods:** Levels of RNF135 expression were measured in glioblastoma and normal brain (NB) tissues samples. Stably decreased expression of RNF135 was established by the pLVTHM-GFP lentiviral RNAi expression system. Molecular mechanisms and the effect of RNF135 on cell growth and migration were investigated using MTT assay, wound healing assay, transwell migration assay, Flow cytometry analysis, western blot assay, immunofluorescence double labeling and tumorigenesis in nude mice.

**Results:** In our study, we confirmed that RNF135 was up-regulated in glioblastoma tissues compared with normal tissues, and RNF135 knockdown inhibited proliferation, migration and cell cycle arrested in G0/G1 phase of glioblastoma U87 cells in vitro. Depressing RNF135 expression, the p-Erk, and cell cycle protein CDK4 were down-regulated while p27<sup>Kip1</sup> and p21<sup>Waf1/Cip1</sup> were up-expressed in U87 cells in vitro. Moreover, the growth of U87 cell-transplanted tumors in nude mice was inhibited by transduced with Lv-shRNF135.

**Conclusion:** Our findings provide the biological effects of RNF135 in glioblastoma cell proliferation, migration and cell cycle, and its role in the progression of glioblastoma may be associated with ERK signal transduction pathway.

doi:10.1016/j.jns.2015.08.655

592

WFN15-0553

**Miscellaneous Topics 1****Evaluation of cognitive functions with p300 in patients with obstructive sleep apnea syndrome**S. Oruc<sup>a</sup>, E. Gunay<sup>b</sup>, F. Karakaya<sup>c</sup>, T. Koyuncu<sup>b</sup>, H. Mayda<sup>d</sup>, D. Kayaalp<sup>a</sup>, M. Yaman<sup>a</sup>. <sup>a</sup>Neurology, Afyon Kocatepe University School of Medicine, Afyonkarahisar, Turkey; <sup>b</sup>Pulmonary Medicine, Afyon Kocatepe University School of Medicine, Afyonkarahisar, Turkey; <sup>c</sup>Neurology, Isparta State Hospital, Isparta, Turkey; <sup>d</sup>Psychiatry, Mardin Kiziltepe State Hospital, Mardin, Turkey

**Introduction:** Hypopnea and apnea in obstructive sleep apnea syndrome (OSAS) lead to end organ hypoxia. This syndrome is an important risk factor for cardiovascular diseases, stroke, hypertension, metabolic syndrome and cognitive impairments. Especially, event-related potentials which are the best indicator for cognitive functions benefit to investigate the physiology of the brain during cognition and give some information about the temporal function. We purposed to investigate the cognitive functions of patients with OSAS via auditory P300 test.

**Methods:** This study was conducted between April 2010 and September 2012. The study population included 53 healthy control and 46 patients with the diagnosis of OSAS confirmed by polysomnography. Auditory P300 test were performed by recording the signals at frontal (Fz), central (Cz) and parietal (Pz) zones.

**Results:** Male to female ratio was 27/19 in OSAS and 24/23 in control ( $p = 0.460$ ). Mean age of OSAS and control was similar both group. In OSAS group, Fz latency was  $345.67 \pm 32.87$ , Cz latency was  $346.91 \pm 36.51$ , Pz latency was  $345.59 \pm 36.04$ . In controls, Fz latency was  $316.55 \pm 39.15$ , Cz latency was  $316.83 \pm 39.05$ , Pz latency was  $314.85 \pm 41.36$ . All these latency parameters were statistically longer in OSAS subjects than in control subjects ( $P < 0.001$  for all). Fz, Cz and Pz amplitudes were similar in both group ( $p = 0.117$ ,  $p = 0.178$ ,  $p = 0.282$ , respectively).

**Conclusion:** We concluded that, longer Fz, Cz and Pz latency recorded with P300 auditory test was found to be an objective indicator for cognitive dysfunction in the OSAS patients.

doi:10.1016/j.jns.2015.08.656

595

WFN15-0980

**Miscellaneous Topics 1****Analysis of effectiveness of conservative methods of treatment of pituitary adenomas**M. Zxhestikova<sup>a</sup>, N. Shakhvorost<sup>b</sup>, V. Minenkov<sup>a</sup>, V. Van<sup>a</sup>, L. Van<sup>a</sup>, N. Keseljev<sup>c</sup>, L. Ma<sup>a</sup>. <sup>a</sup>The chair of medical rehabilitation and reflex therapy, Novokuznetsk State Post Graduate Medical Institute, Novokuznetsk, Russia; <sup>b</sup>Department of endocrinology, Munisipal Hospytal 1, Novokuznetsk, Russia; <sup>c</sup>Department of neurology, Munisipal Hospital 29, Novokuznetsk, Russia

**Background:** The growth of volume of pituitary adenomas is accompanied by neurological, endocrinological disorders, increasing blood pressure.

**Objective:** To carry out analysis of results of conservative methods of treatment of pituitary adenomas.

**Patients and methods:** The research was carried out in the industrial centre of South - West Siberia. The analysis of pituitary adenomas was made 1998 to 2014 with the help of retrospective, analytical statistical methods of research. It was revealed that 299 people at the age of 20 - 50 years old were ill. The average age is  $41,08 \pm 0,89$  among them there are 75 man, 224 women. Prolactinomas are found in 53,51%. On the second place there are hormone inactive pituitary adenomas 35,11%. Somatotropinomas were diagnosed in 11,38% cases. The treatment of pituitary adenomas was carried out with consideration of clinics - biochemical, MRI data and it included medicamentous monotherapy, surgical intervention or radiation or the combination of these methods in different variations.

**Results:** When conservative therapy was used as monotherapy 76,9%, patients had regress of tumour in 56,08% cases, stabilization of the process was in 31,79%, continual growth in 12,13% cases. Using agonists of dopamine in conservative treatment of patients with prolactinoma - regress of tumour was obtained in 82,14%. Treating patients, who had somatotropinomas, with analogues of somatostatine, regress of tumour was obtained in 91,66%. Using agonists of dopamine in treatment of hormone inactive pituitary adenomas, regress of tumour was obtained in 4,22%.

**Conclusion:** Conservative methods of treatment lead to regress of tumour, causing less complication.

doi:10.1016/j.jns.2015.08.657



596

WFN15-0507

## Miscellaneous Topics 1

## Sleep problems in patients with Parkinson's disease (PwPD) of the Siberian Region Russia

M. Nikitina<sup>a</sup>, I. Zhukova<sup>a</sup>, V. Alifirova<sup>a</sup>, N. Zhukova<sup>a</sup>, M. Zhestikova<sup>b</sup>, M. Titova<sup>a</sup>, E. Koroleva<sup>a</sup>, E. Terskikh<sup>a</sup>, J. Mironova<sup>a</sup>, O. Izholdina<sup>a</sup>.

<sup>a</sup>Department of neurology and neurosurgery, Siberian state medical university, Tomsk, Russia; <sup>b</sup>Department of neurology, Novokuznetsk State Postgraduate Institute, Novokuznetsk, Russia

**Objective:** examination of sleep problems and investigation of associated factors, with special emphasis on disease stage, age and sex in PwPD.

**Background:** Sleep problems are presented at any stage of PD causing both nocturnal and diurnal changes to the physiologic sleep pattern.

**Methods:** PwPD completed a self-report questionnaire, which consisted of demographic variables, information of PD, such as date of diagnosis and initiating therapy, dosage, and instruments for assessment of sleep disturbances. The severity of PwPD was estimated using H&Y Scale, UPDRS. The MoCA-test was used for evaluating cognitive impairment, the PDQ-39—for quality of life, the HADS—for evaluating anxiety and depression, the Epworth Sleepiness Scale(ESS)—for quantifying excessive daytime sleepiness(EDS).

**Results:** 766 PwPD are registered in movement disorders electronic database of the Siberian region. 166 PwPD were included (women:men = 98:68, the mean age was  $66.9 \pm 9.5$ ). The mean duration of PD was  $7.2 \pm 5.3$ , the mean H&Y stage— $2.56 \pm 0.57$ . The mean UPDRS III was  $32.9 \pm 11.7$ , MoCA— $22.9 \pm 4.3$ . The mean of total ESS score was  $13.7 \pm 4.5$ . Among the PwPD 67.5% of patients had EDS(24.1% had pathological EDS, 43.4%—medium). After detailed examination of PwPD with EDS was observed that EDS correlates with insomnia, nightmares, sleep attacks, REM sleep behavior disorder, restless legs syndrome(RLS), sleep apnea, nocturia. Sleep-related problems were most prominent in patients with advanced disease( $p < 0.05$ ) and high dose dopamine replacement therapy( $p < 0.05$ ).

**Conclusions:** Study is focusing on multifactorial sleep problems of PwPD especially in association with mental health problems, fatigue and RLS. Disease-related individual factors contribute to the degree, severity and type of sleep problems.

doi:10.1016/j.jns.2015.08.658

597

WFN15-0395

## Miscellaneous Topics 1

## Working memory compromise in sleep apnea syndrome and the impact on the cognitive potential p300

A. Zúñiga-Fajuri, M. Silva-Aguilera, J. Landerretche, D. Lister, C. Aguilera-Arriagada, D. de Larraechea. *Neurology, Chilean Air Force Hospital, Santiago, Chile*

**Background:** Obstructive Sleep Apnea Syndrome provokes the disruption of normal sleep structuration, characterized by increased of superficial sleep at the expense of deep sleep and REM, leading to cognitive disorders of attention and working memory.

**Objective:** Evaluate the degree of alteration in working memory and attention and in OSAS patients, using neuropsychological tests, and correlate the results with the P300 evoked potential.

**Methods:** Linear regressions were used to evaluate the causal impact of the variables. The OSAS category was represented by dichotomous variables and estimated with the STATA program. The statistical and joint significance was evaluated via *t-statistics* and *F test*, respectively. Scatter plots were made with Matlab software.

**Results:** There is a positive causal and statistically significant impact of moderate OSAS patients on the P300 response, i.e., moderate OSAS experienced a greater latency of the P300 response than those with mild OSAS. The same occurred with severe OSAS with an RDI up to 50. A statistically significant relationship between age and P300 was also found. A causal link with a statistical significance was found between P300 and neuropsychological tests.

**Conclusion:** The latency of the P300 response is a quantitative indicator of cortical processing speed and working memory. Consequently, patients with moderate OSAS have lower cognitive processing speed and working memory than patients with mild OSAS. This is repeated in severe OSAS with an RDI up to 50 compared to moderate ones. Finally, OSAS patients with altered neuropsychological tests, show a correlation with the P300 response.

doi:10.1016/j.jns.2015.08.659