

nerve peripheral nerve peripheral nerve peripheral nerve peripheral nerve peripheral nerve peripheral nerve peripheral nerve
nerve peripheral nerve peripheral nerve peripheral nerve peripheral nerve peripheral nerve peripheral nerve peripheral nerve
peripheral nerve peripheral nerve
nerve peripheral nerve peripheral nerve peripheral nerve peripheral nerve peripheral nerve peripheral nerve peripheral nerve

hera

Ultrasound guided intervention on peripheral mononeuropathy

Gerd Bodner

Department of Biomedical Imaging and Image-guided Therapy
General Hospital of the Medical University of Vienna

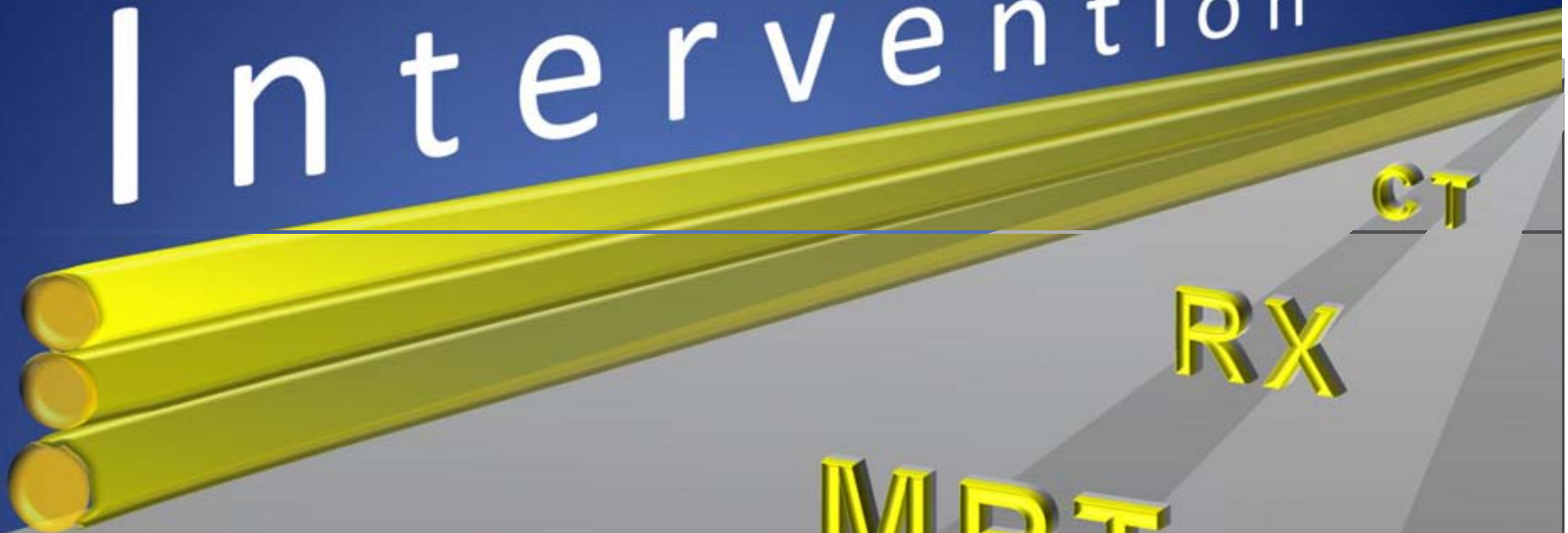Intervention

CT

RX

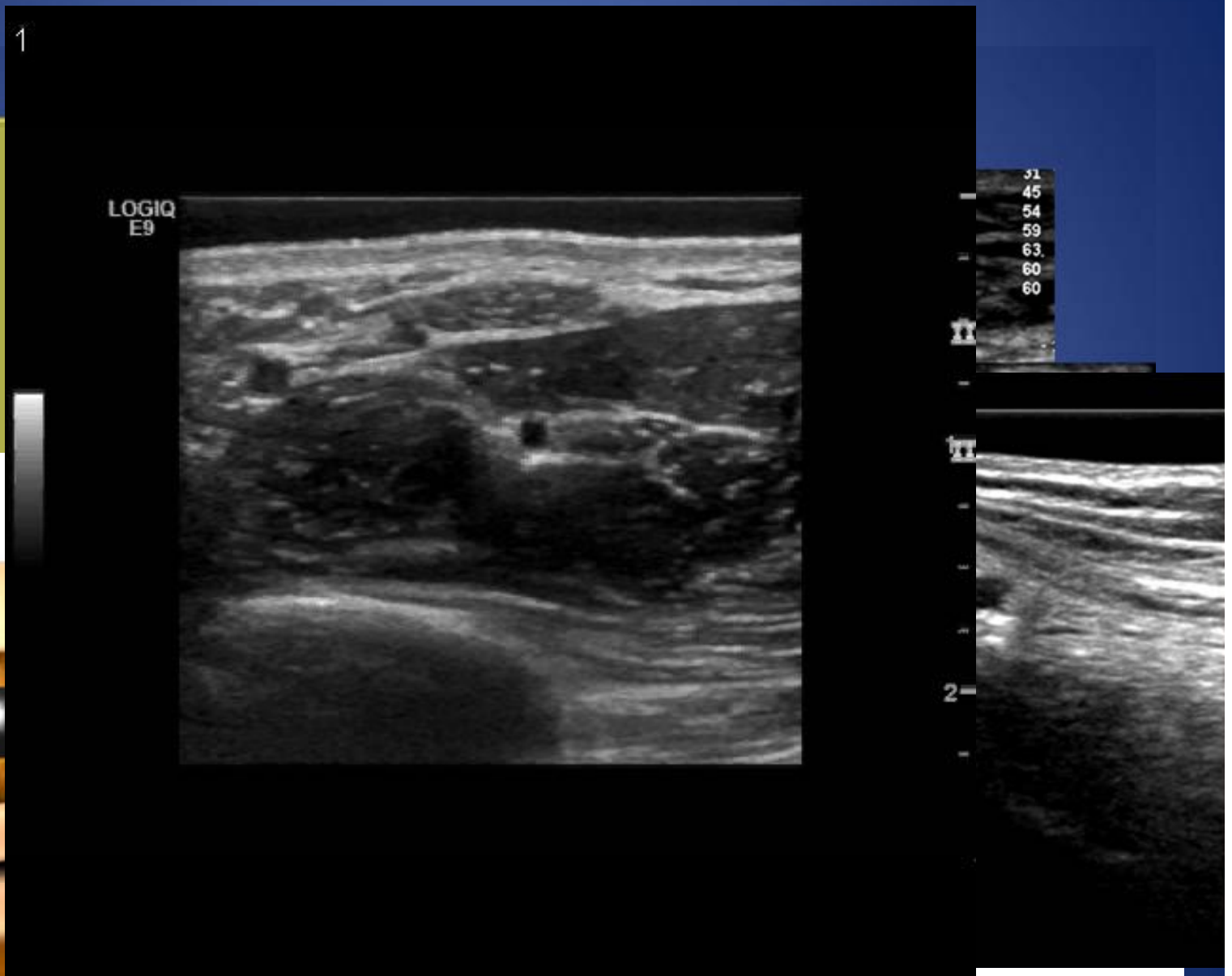
MRT

ULTRASOUND



WHY ULTRASOUND

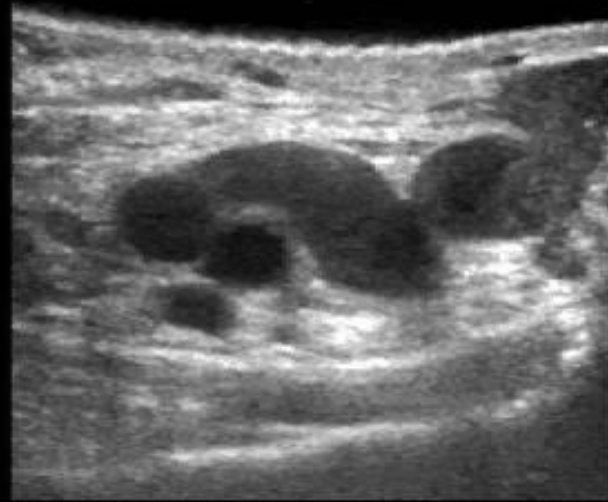




Ultrasound of the lateral femoral cutaneous nerve: normal findings in a cadaver and in volunteers. Reg Anesth Pain Med. 2009
Bodner G et al

1

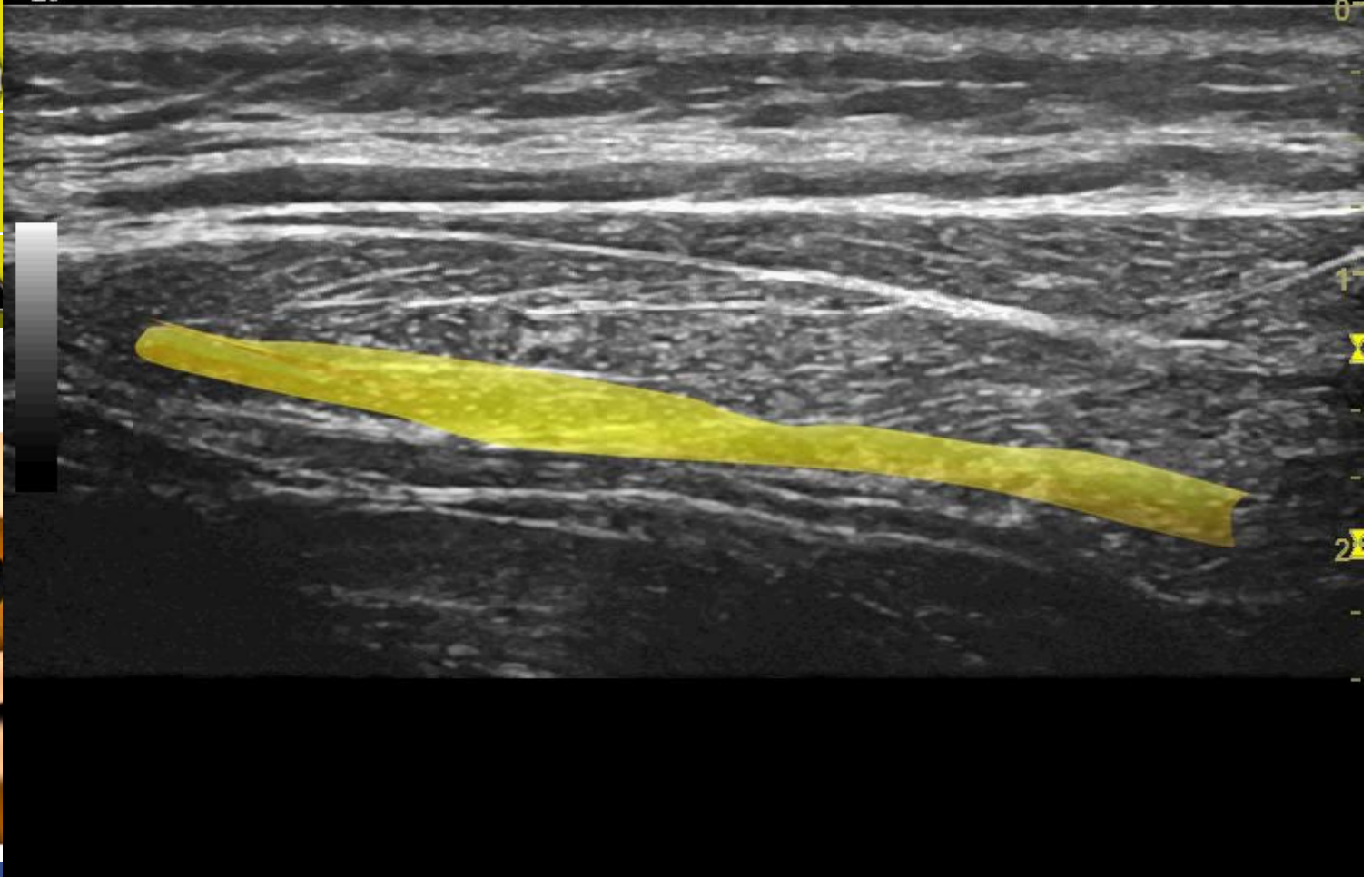

LOGIQ
E9

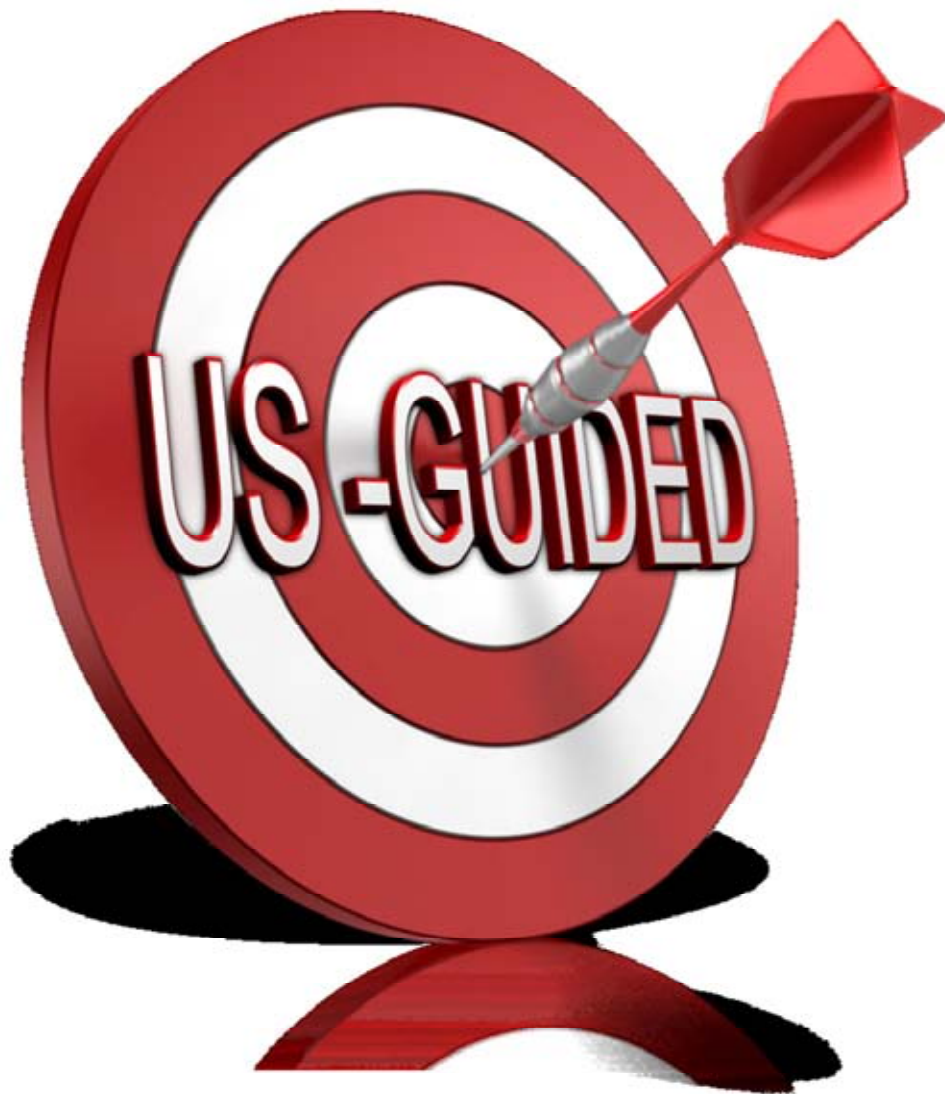

06/09/13
06/09/13

RIGHT

LOGIQ
E9





See the nerve
See the needle
Cheap
Portable
Small dosis
No radiation

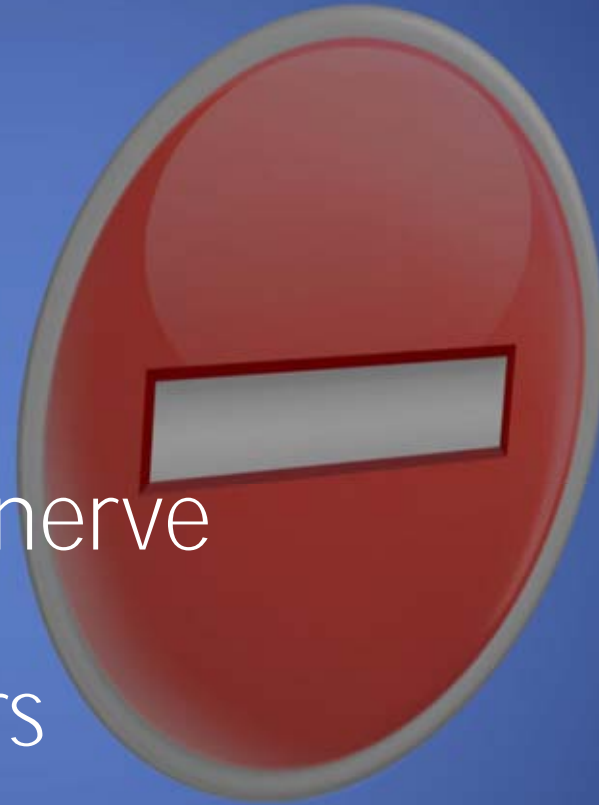
Pain Physician. 2008

Ultrasound-guided interventional procedures for patients with chronic pelvic pain - a description of techniques and review of literature.

Peng PW, Tumber PS.

Ultrasound guided intervention on peripheral mononeuropathy

- Experience
- Equipment
- Deep running nerve
- Air, bone , scars



When to perform US guided N-I

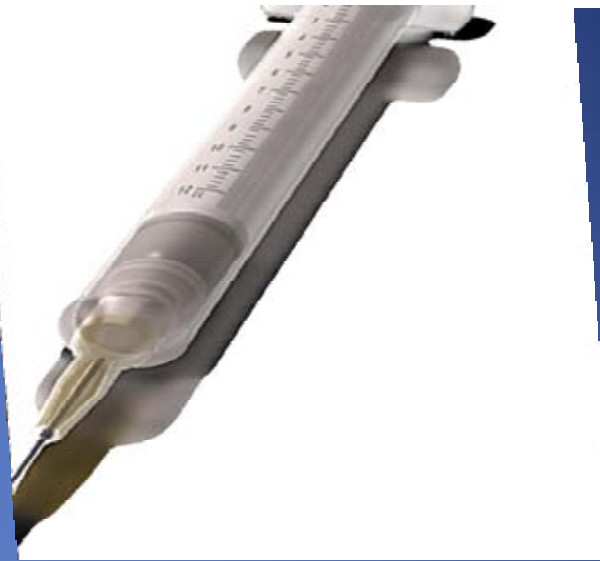- Inconclusive clinical/imaging
- Conservative treatment failed



Prerequisites for US guided N-I :


- Patient approval
- Blood work
- Experience/equipment
- Diagnosis
- Therapeutic success
- Complication-management

How to do



In plane technique

How not to do



Out of plane technique



US –guided Diagnosis and Therapy on peripheral neuropathies

Nerve block

Fine needle aspiration

Biopsy

Therapeutic injection

Thermal Ablation/Denervation

Diagnostic US-guided Nerve block

Sensoric compression syndrom

Complex nerve compression
TOS, Pudendal neuropathy

Advantage small dose of local anesthetic



Meralgia paresthetica

Compression of lateral femoral cutaneous nerve

Pain

Dysesthesia

Overweight

Pregnancy

Belt/jeans

Iatrogenic

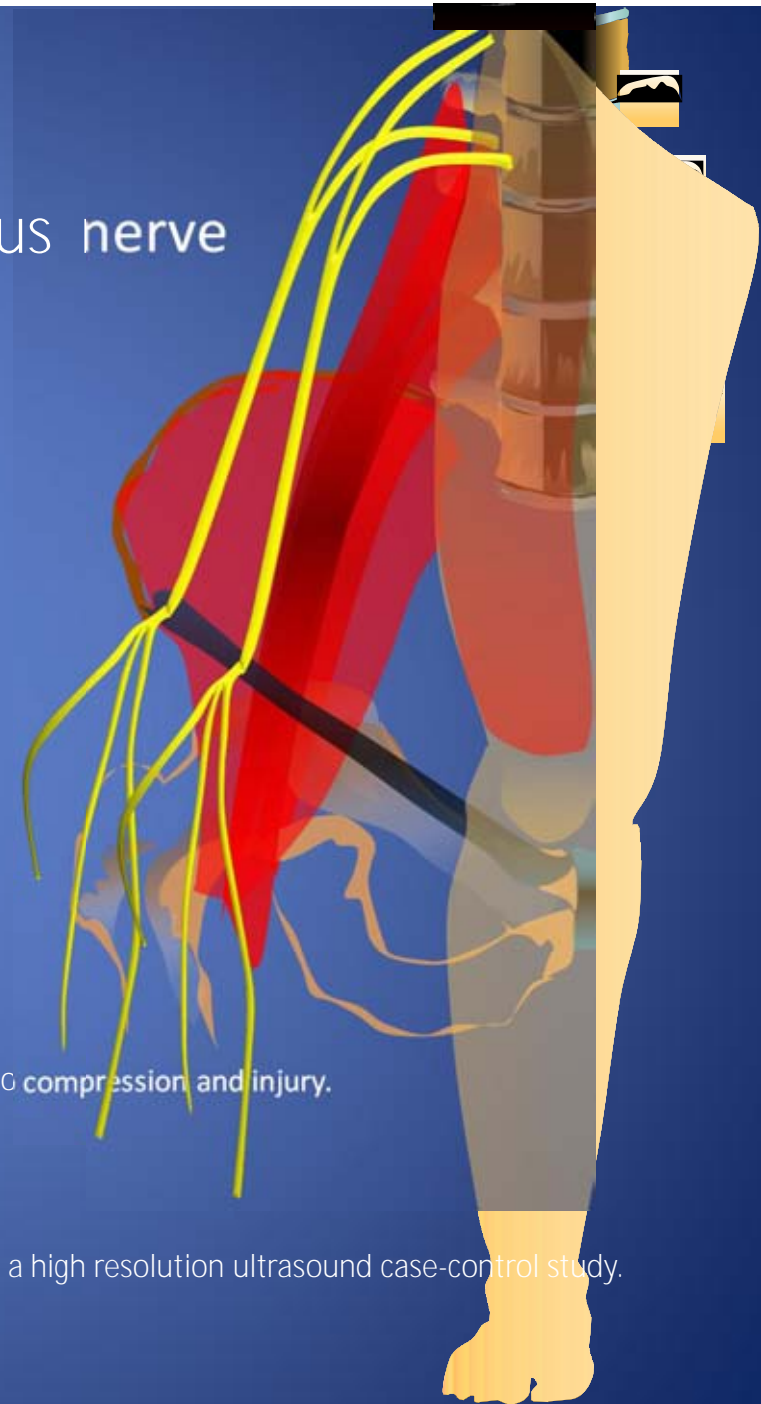
1997 Plast Reconstr Surg

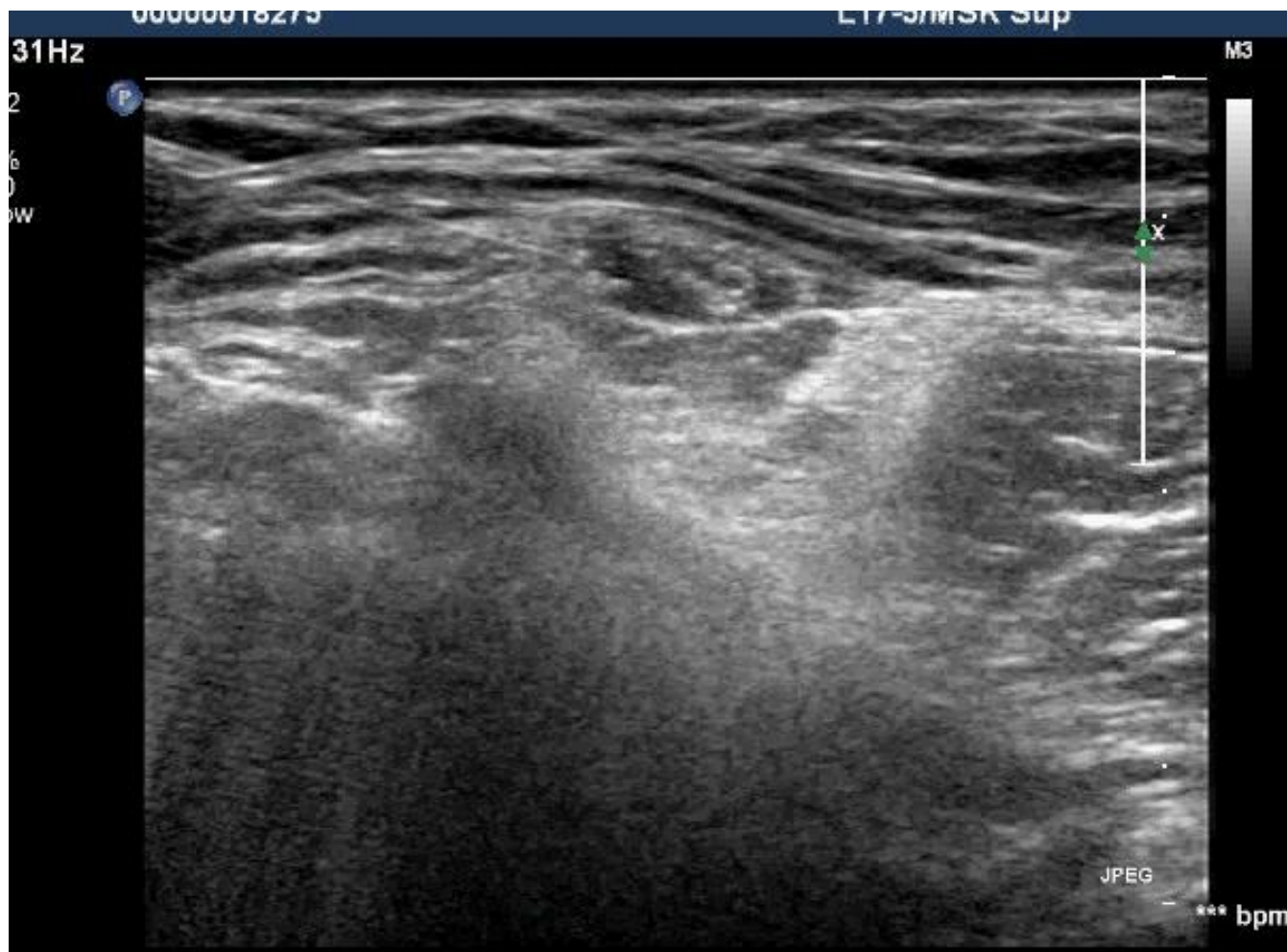Anatomical course of the lateral femoral cutaneous nerve and its susceptibility to **compression and injury**.

Aszmann OC, Dellon ES, Dellon AL.

Common anatomical variation in patients with idiopathic meralgia paresthetica: a high resolution ultrasound case-control study.


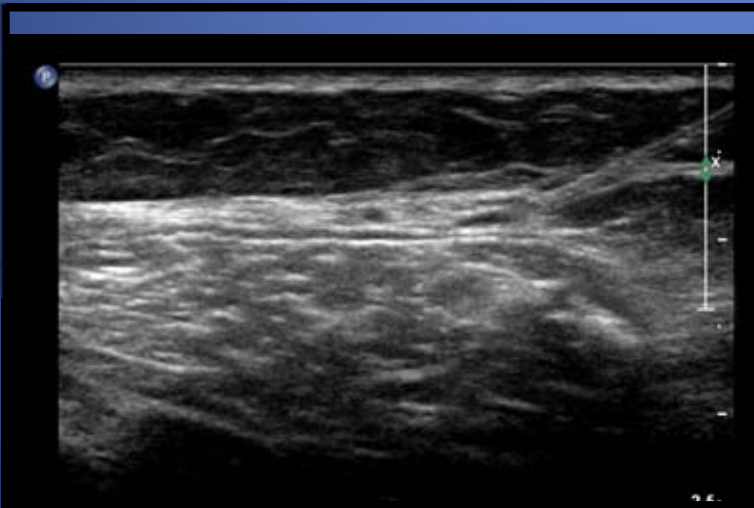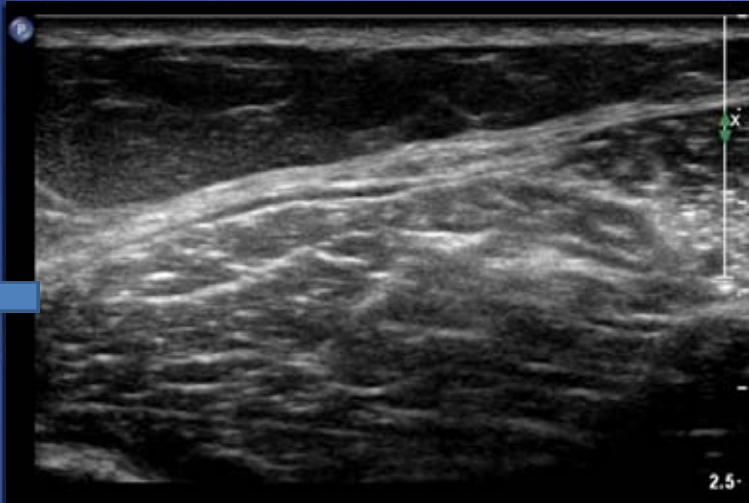

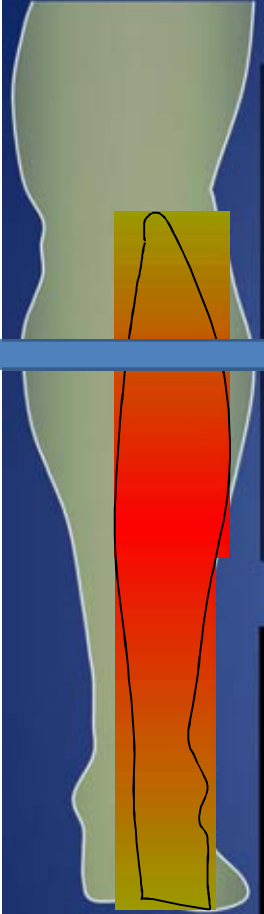
Moritz T, Bodner G. Pain Physician 2013

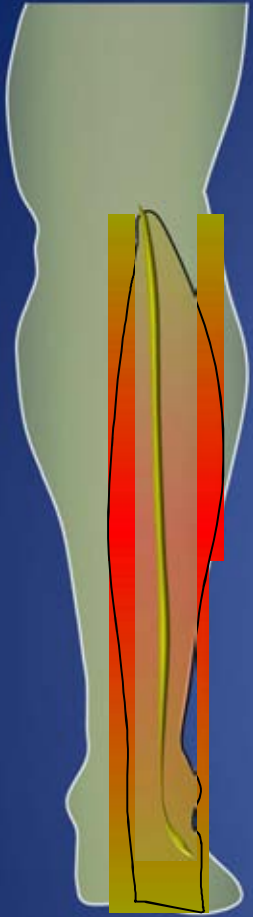




Tagliafico A. et al. J Ultrasound Med. 2011
Ultrasound-guided treatment of meralgia paresthetica
(lateral femoral cutaneous neuropathy): technical
description and results of treatment in 20 consecutive
patients.

Sural nerve-Syndrom





PHILIPS USR
07341720100204

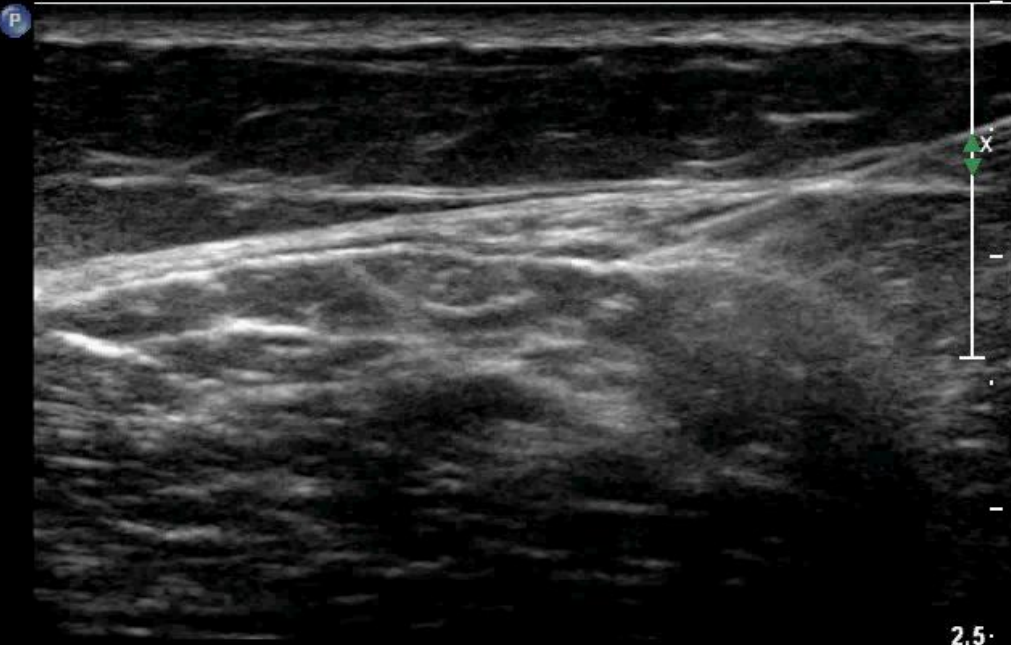
04/02/2010 17:45:12 TIS0.0 MI 0.4

L17-5/MSK Sup

FR 35Hz
RS

M3

2D
54%
C 60
P Med
Res



2.5
JPEG

*** bpm

Fine Needle Aspiration

Postsurgical Seroma (femur)

Ganglion

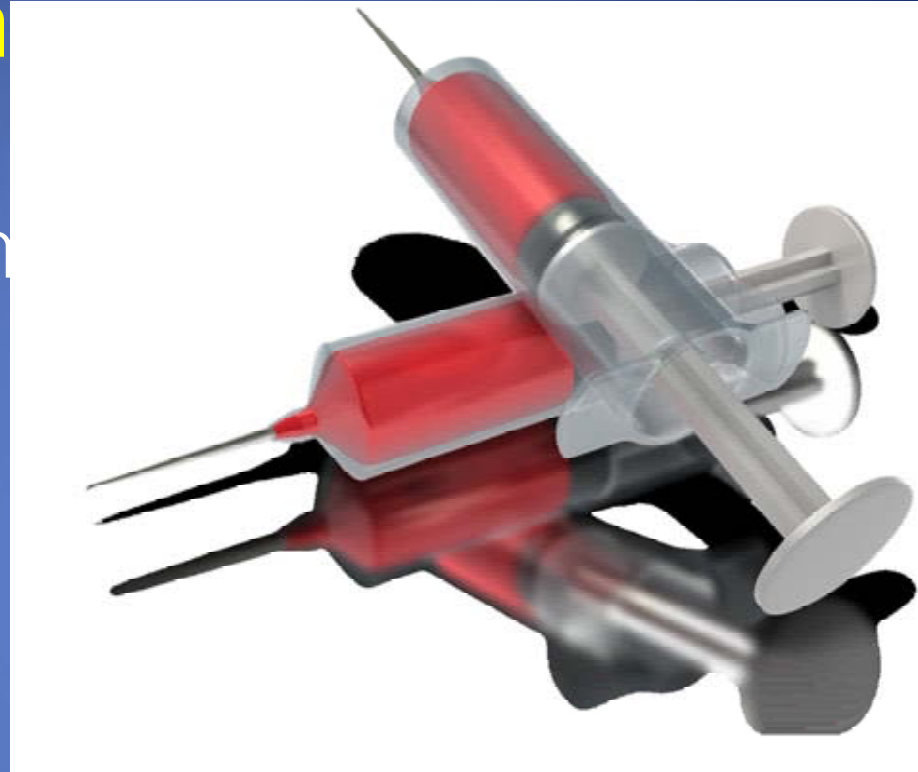
Extraneural

Intraneural

Tibio-fibular

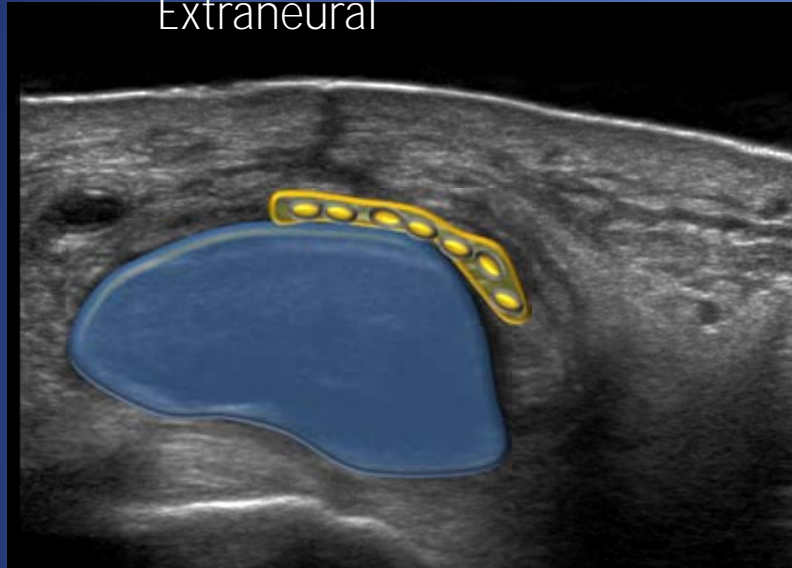
Glenoid notch

Carpal-Tarsal tunnel

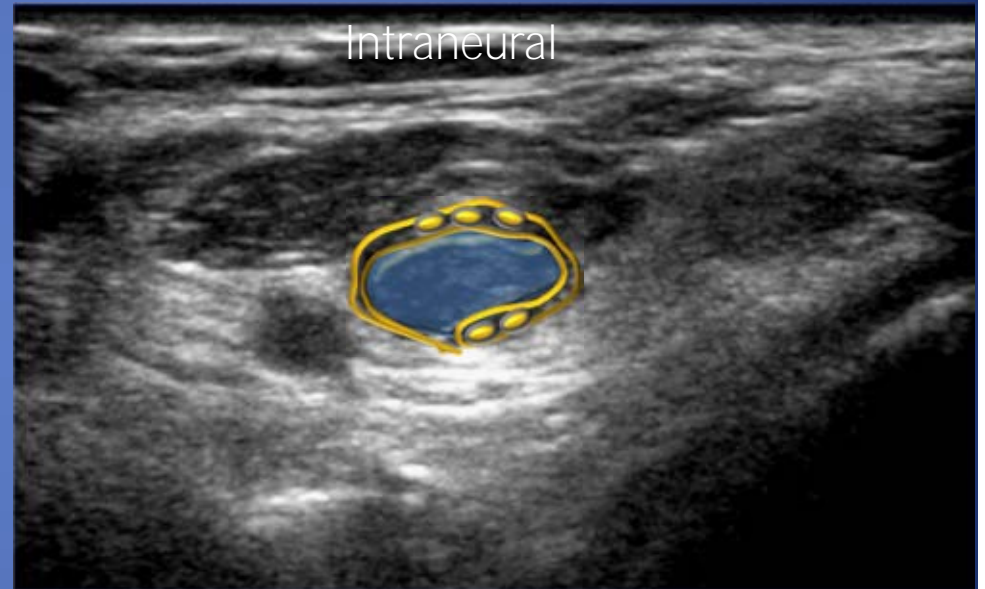


Fine Needle Aspiration

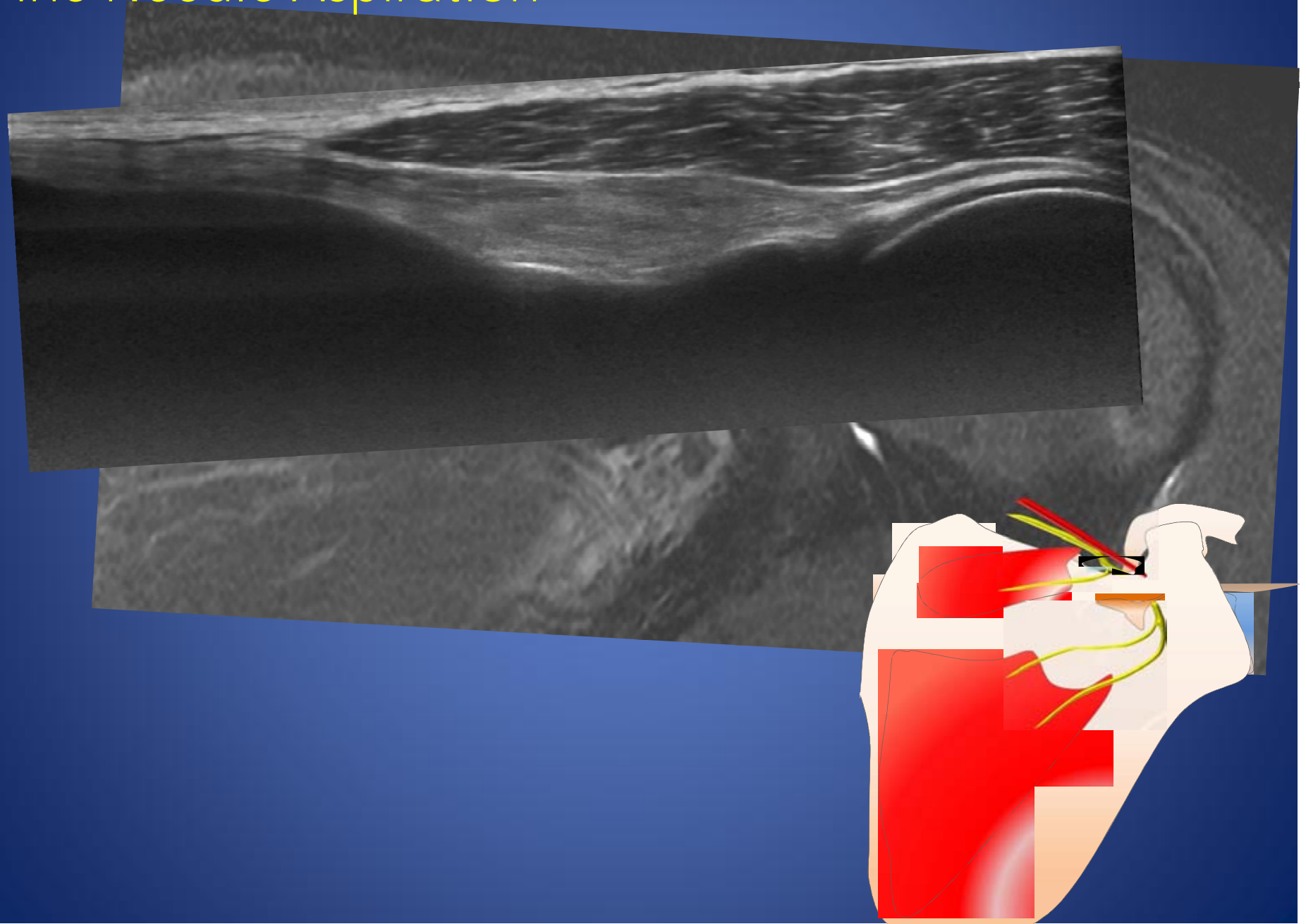
Extraneural




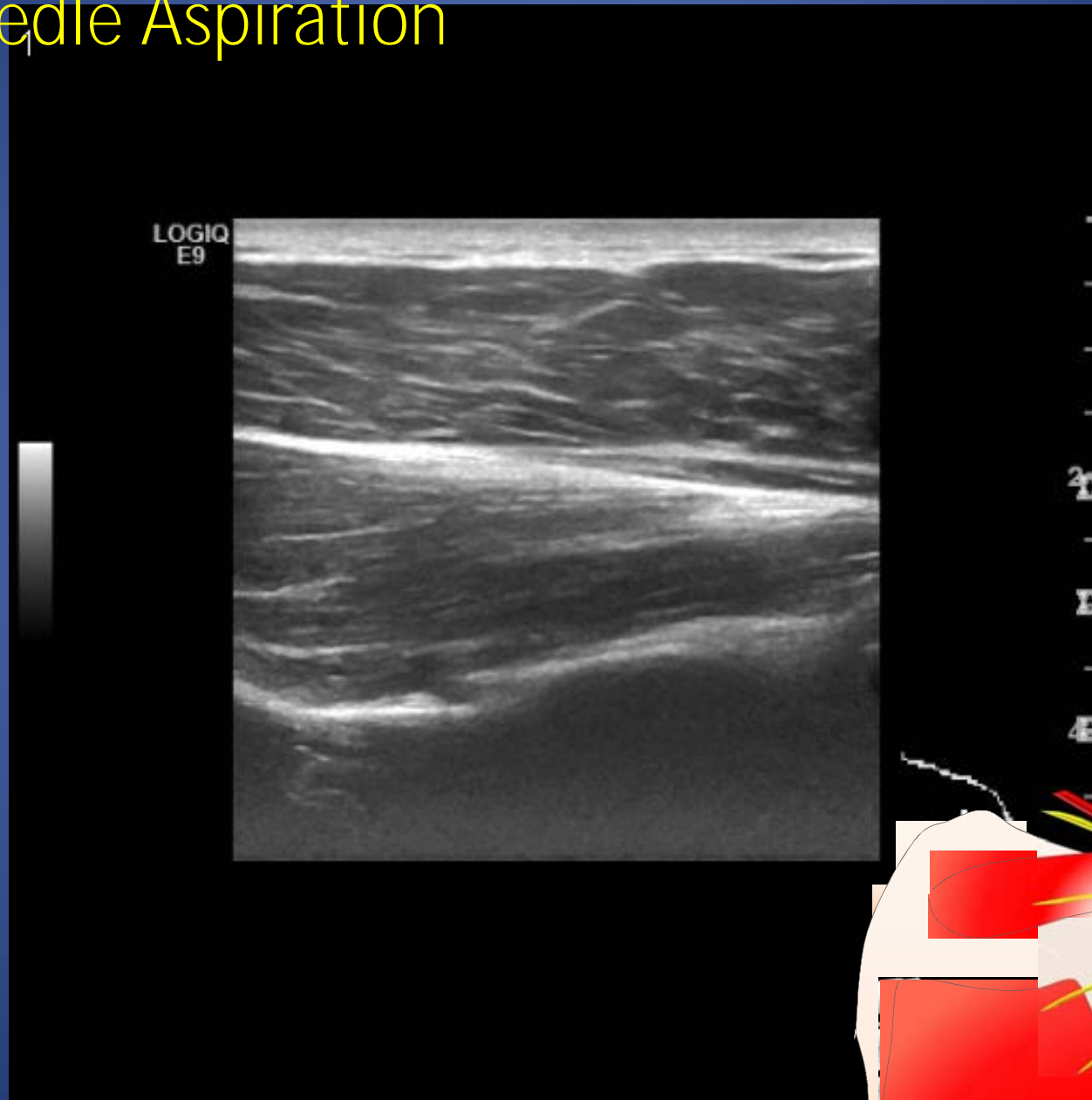
Intraneural




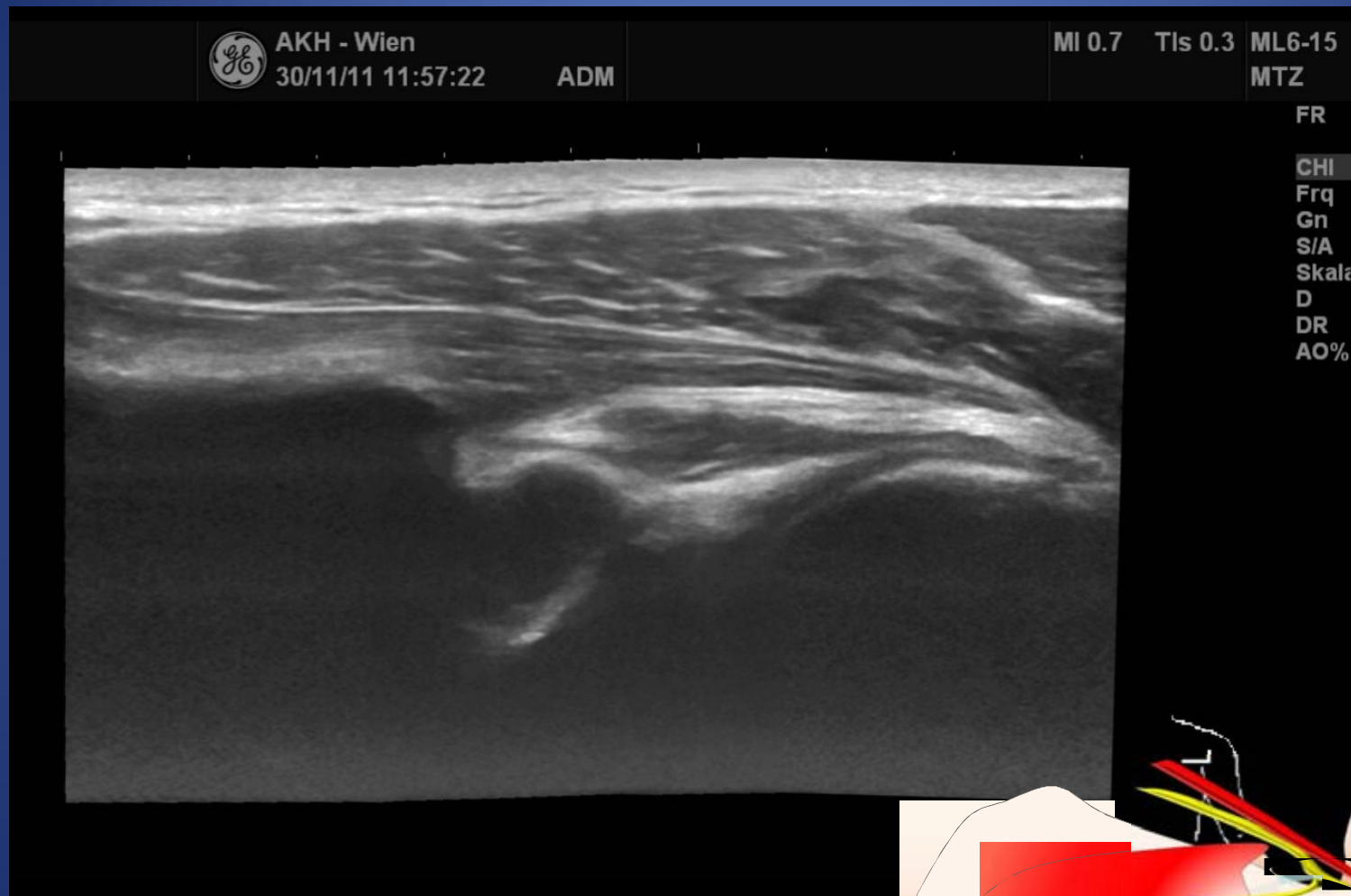
Fine Needle Aspiration



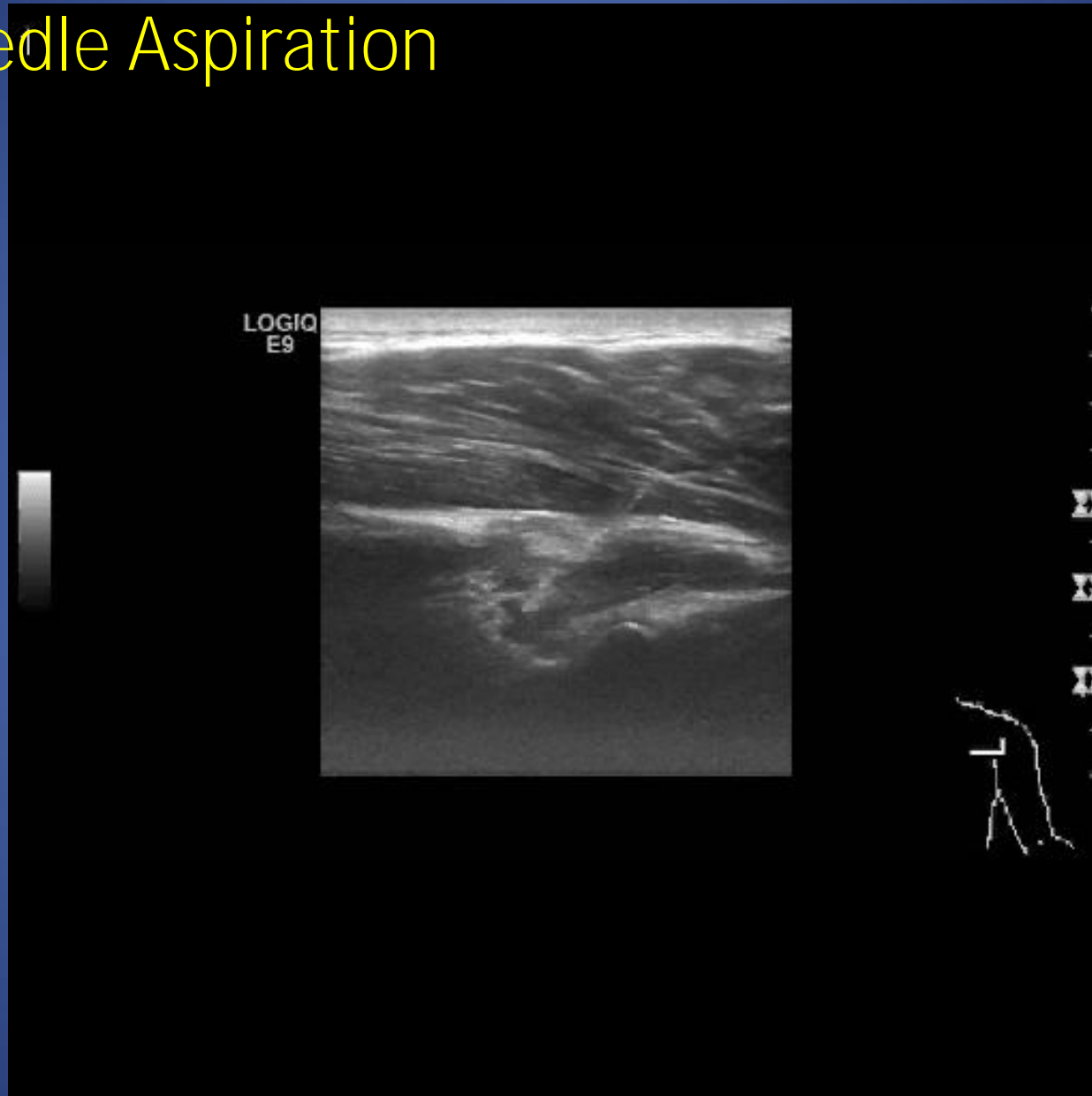
Fine Needle Aspiration




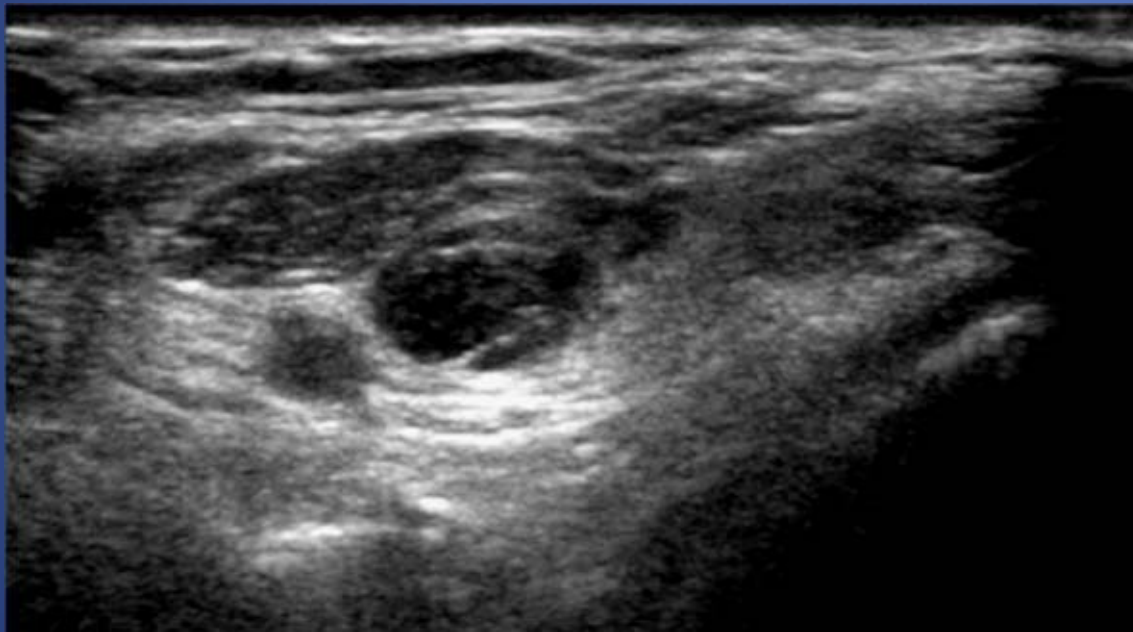
Fine Needle Aspiration




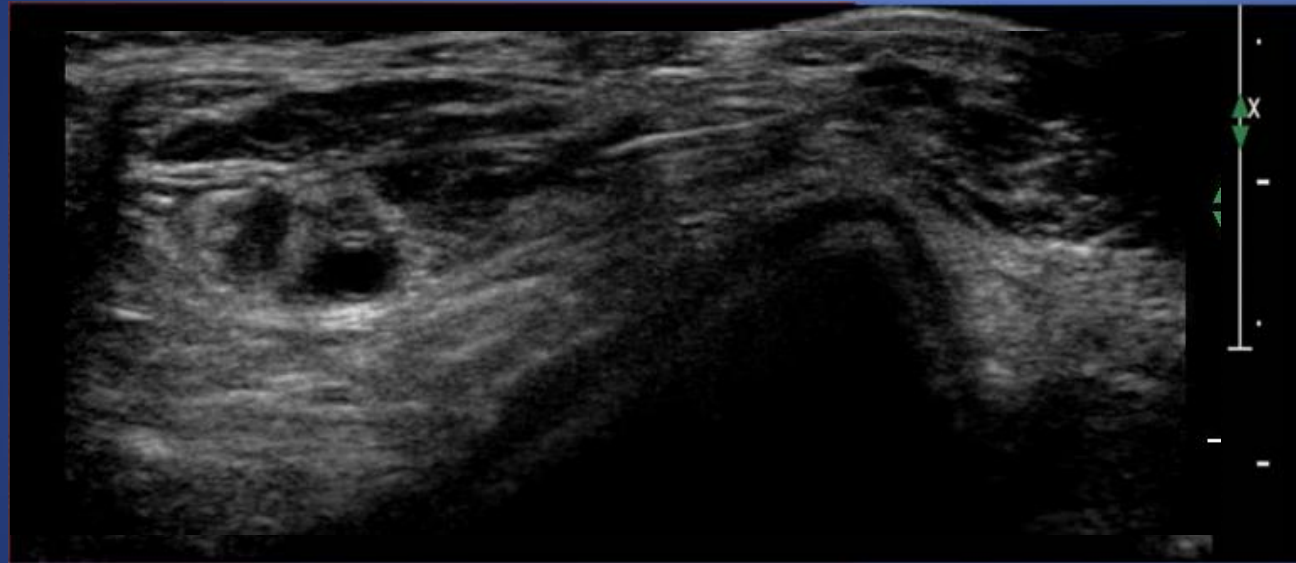
Fine Needle Aspiration



Fine Needle Aspiration



Fine Needle Aspiration



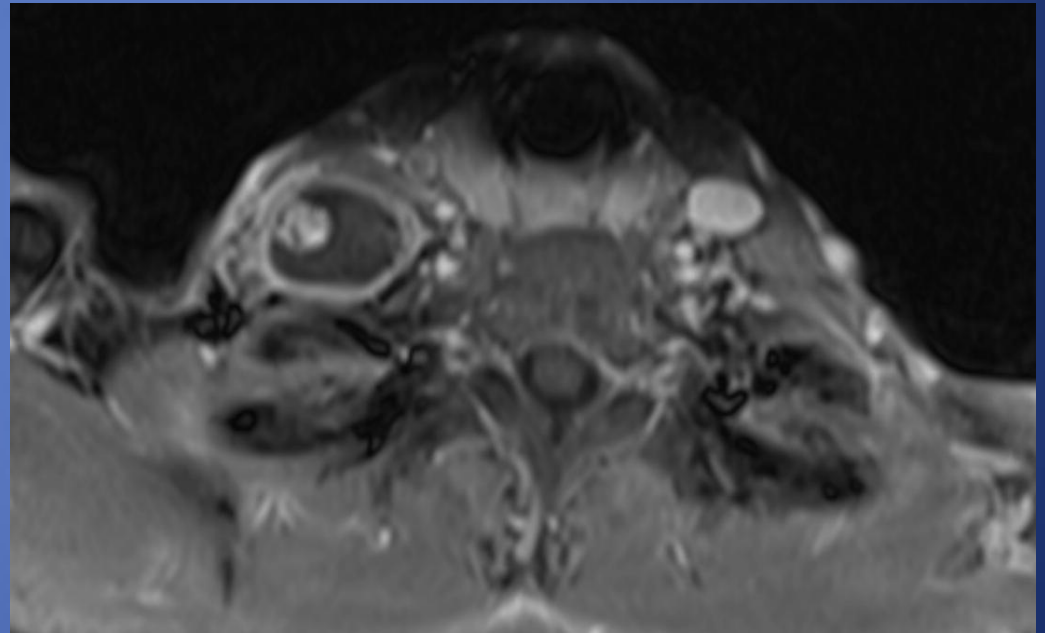
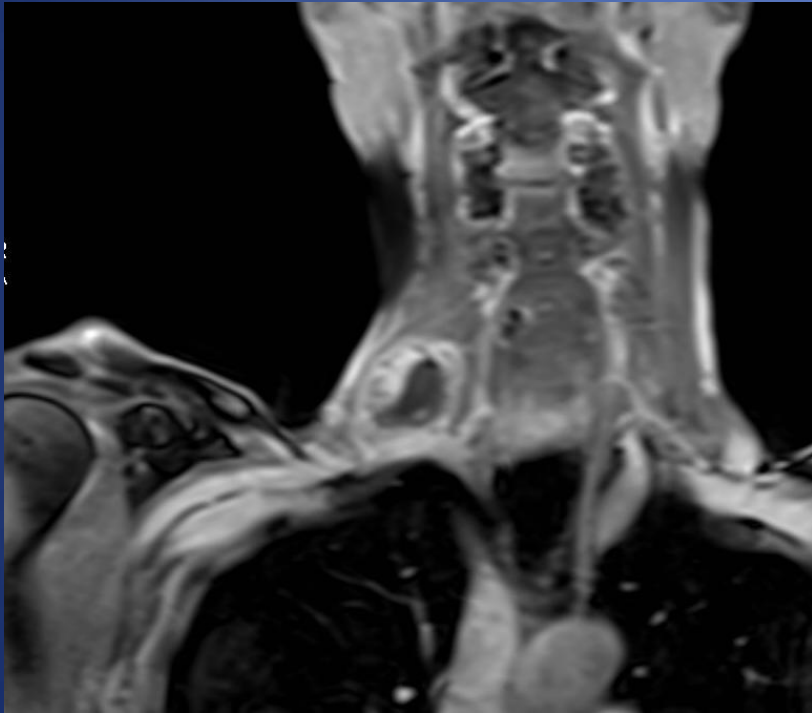
Biopsy of peripheral Nerve tumors, tumors compressing nerves

Only performed in Tumor centers

Only after tumor board meeting

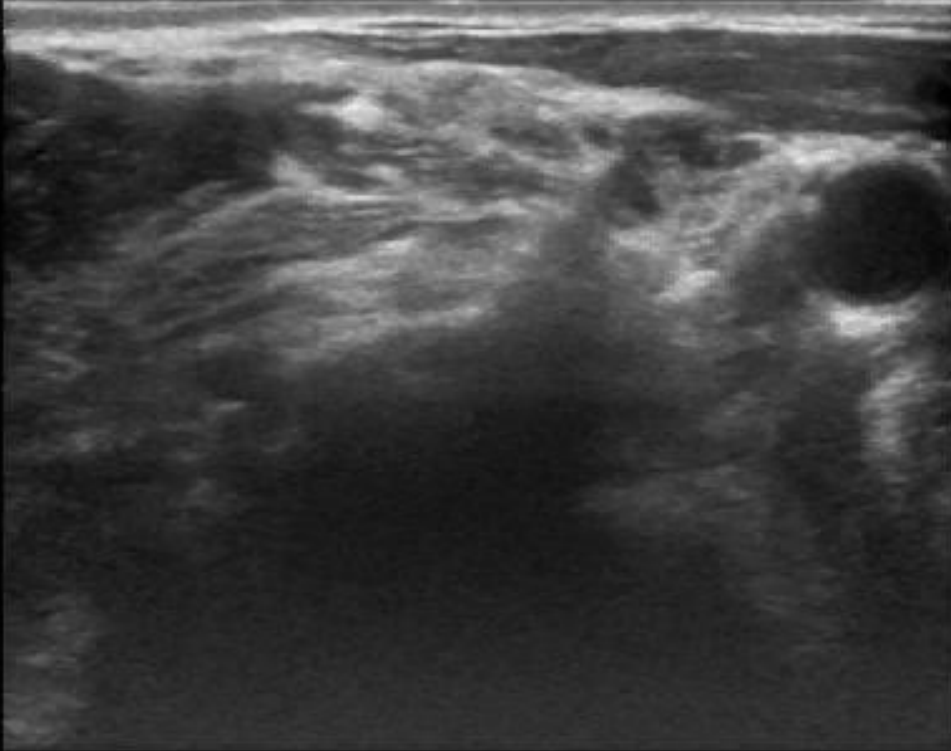
Suspected malignancy

Biopsy




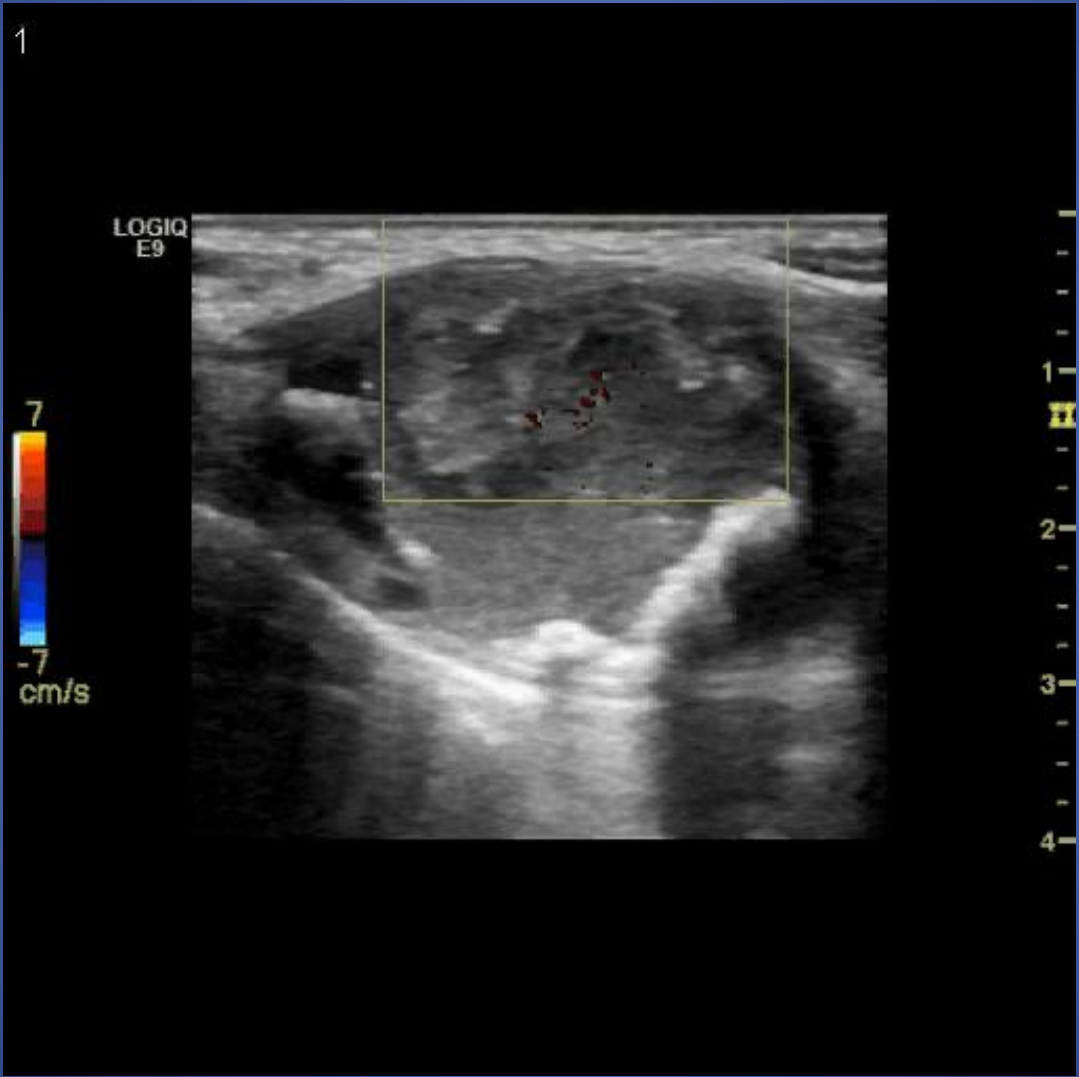
1

LOGIQ
E9

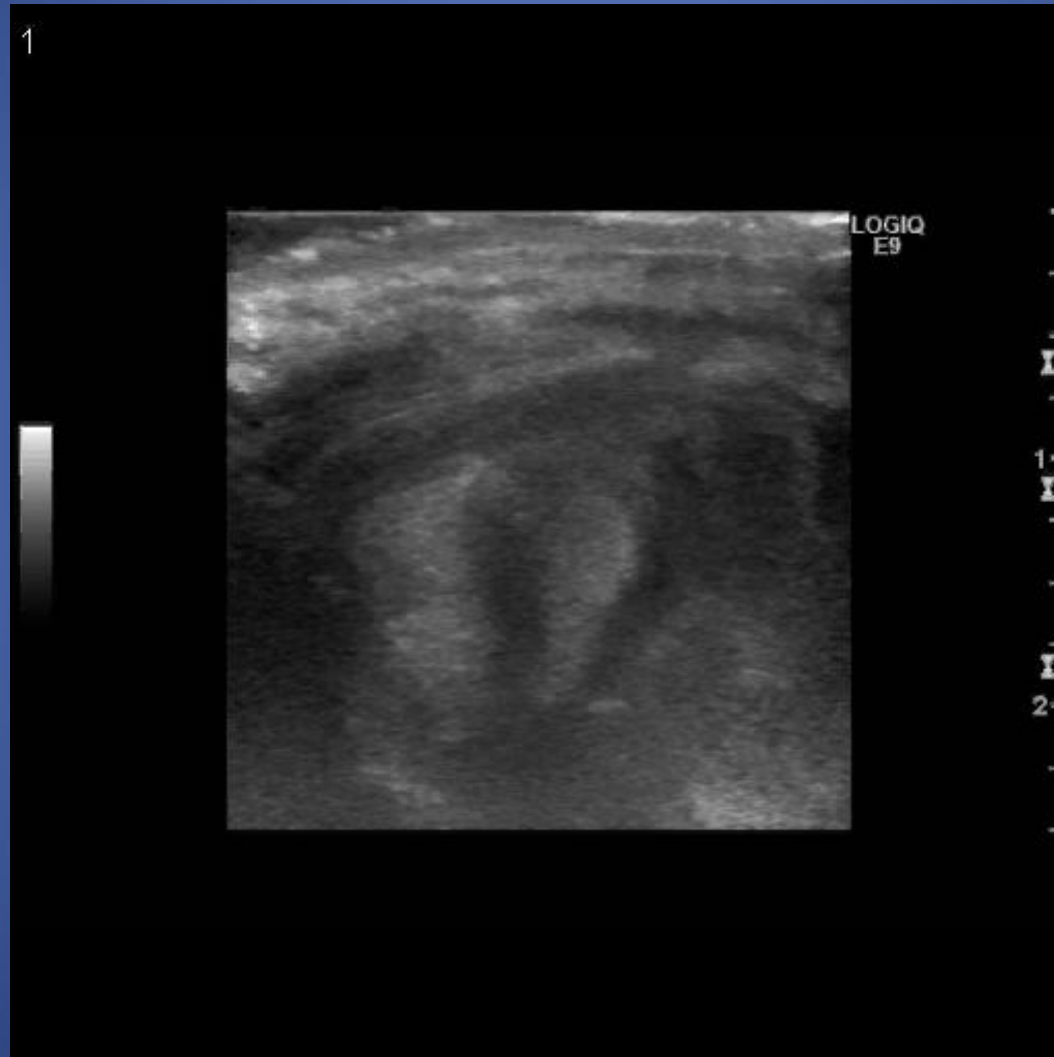


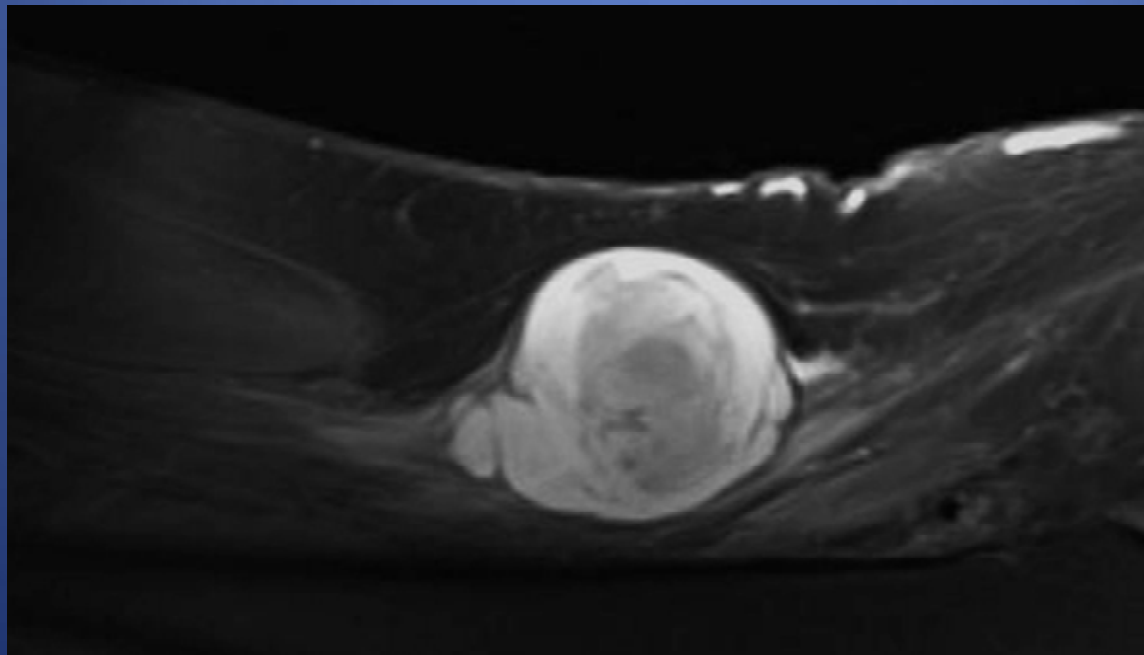
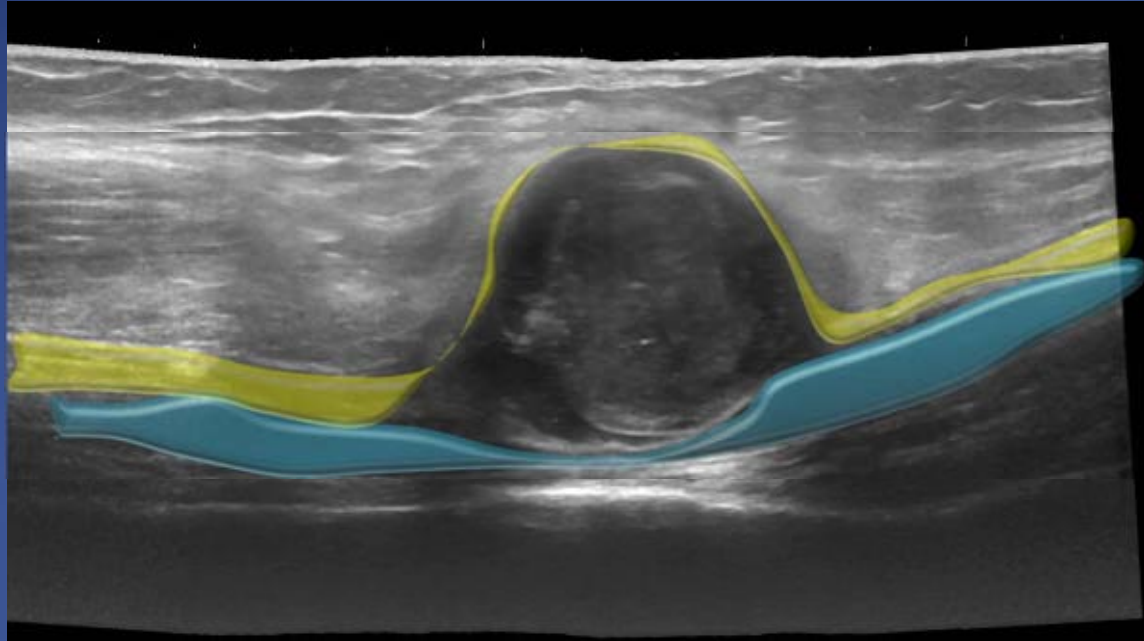
1
II
2
II
3
4






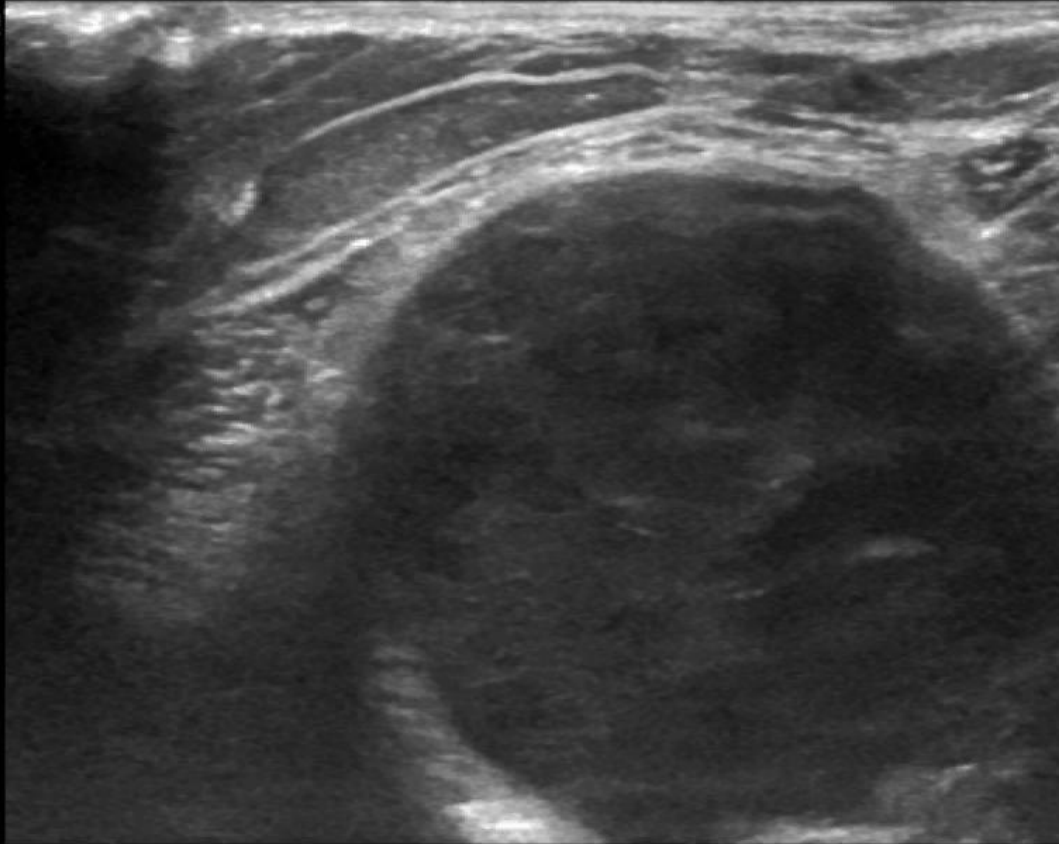
Venous Malformation

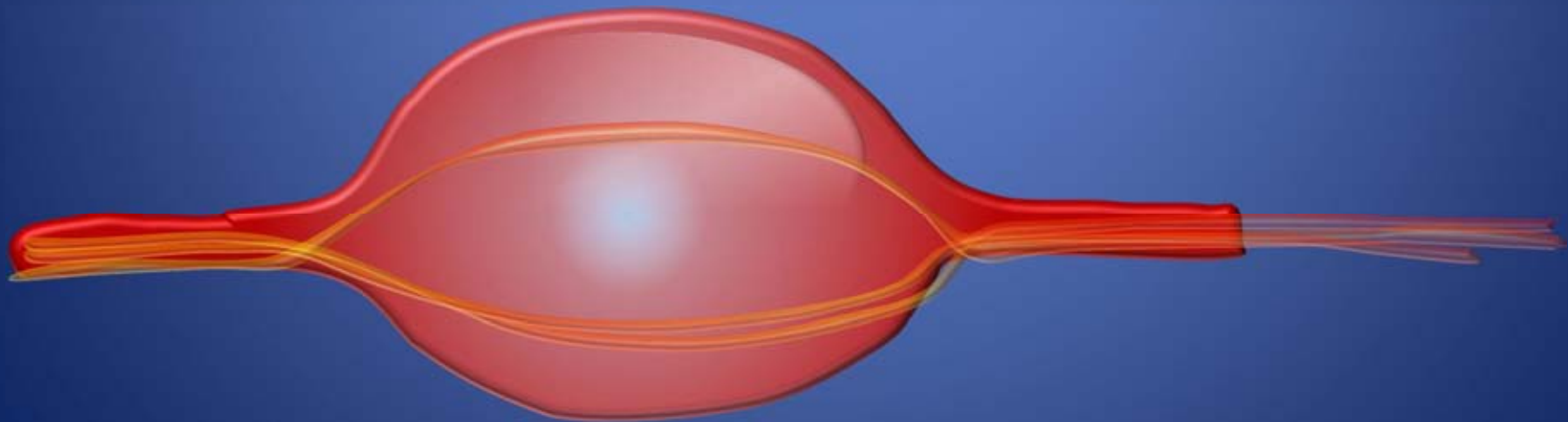
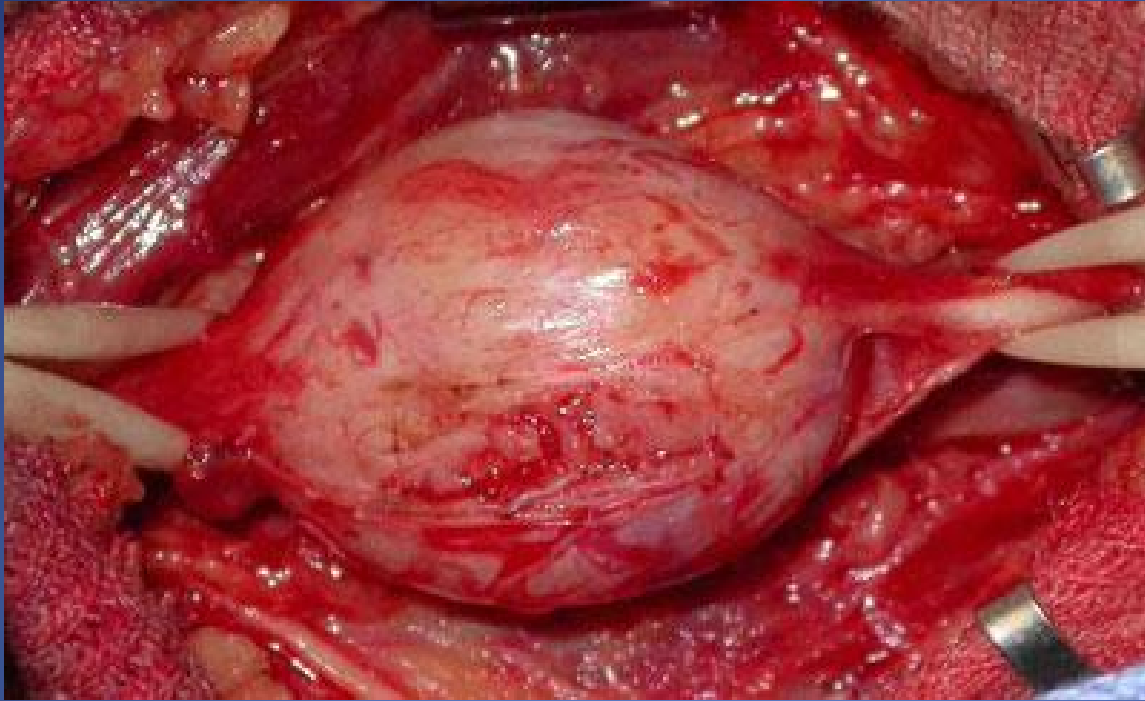




1

LOGIQ
E9






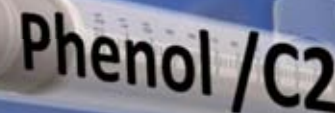
Therapeutic Injection



Corticosteroids



Hyaluron



Phenol /C2



Glyzerol




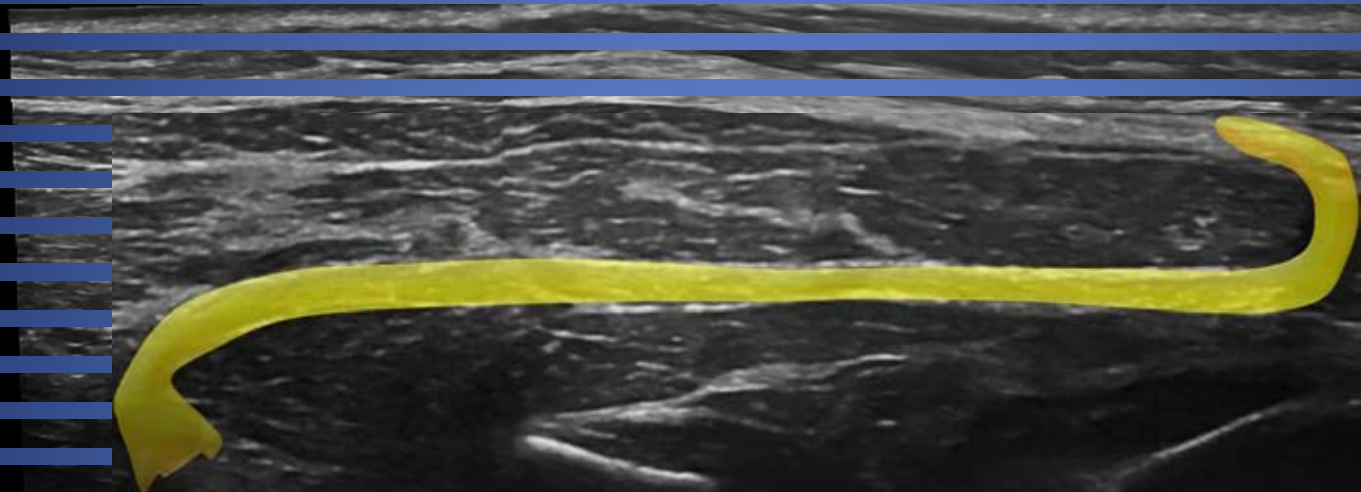
Botox



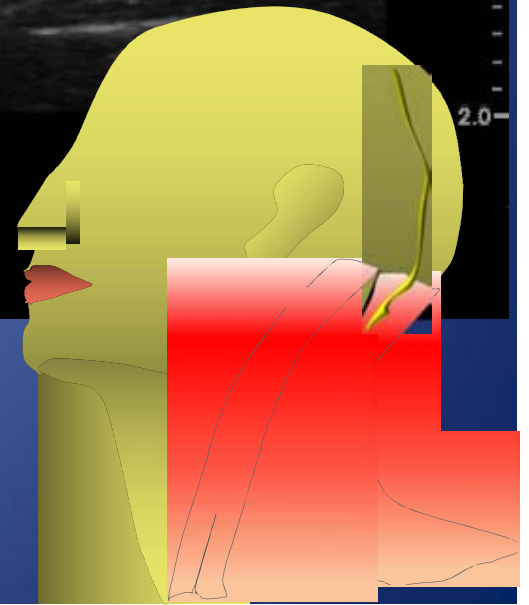
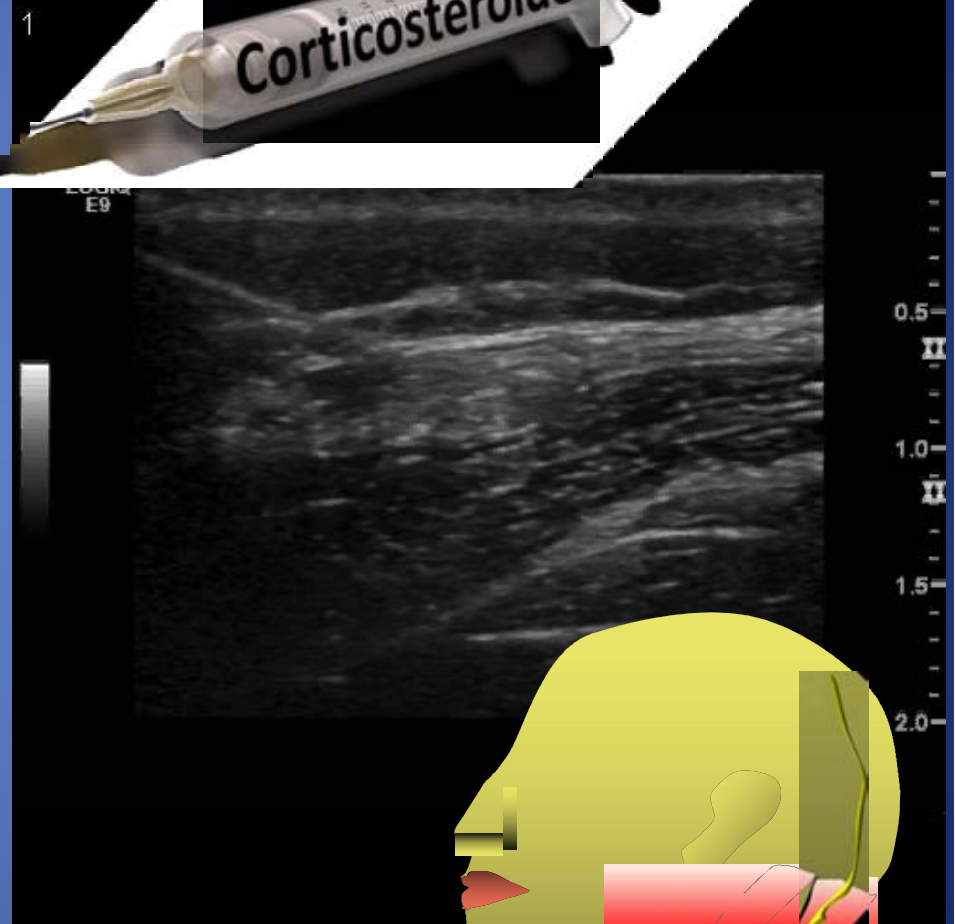
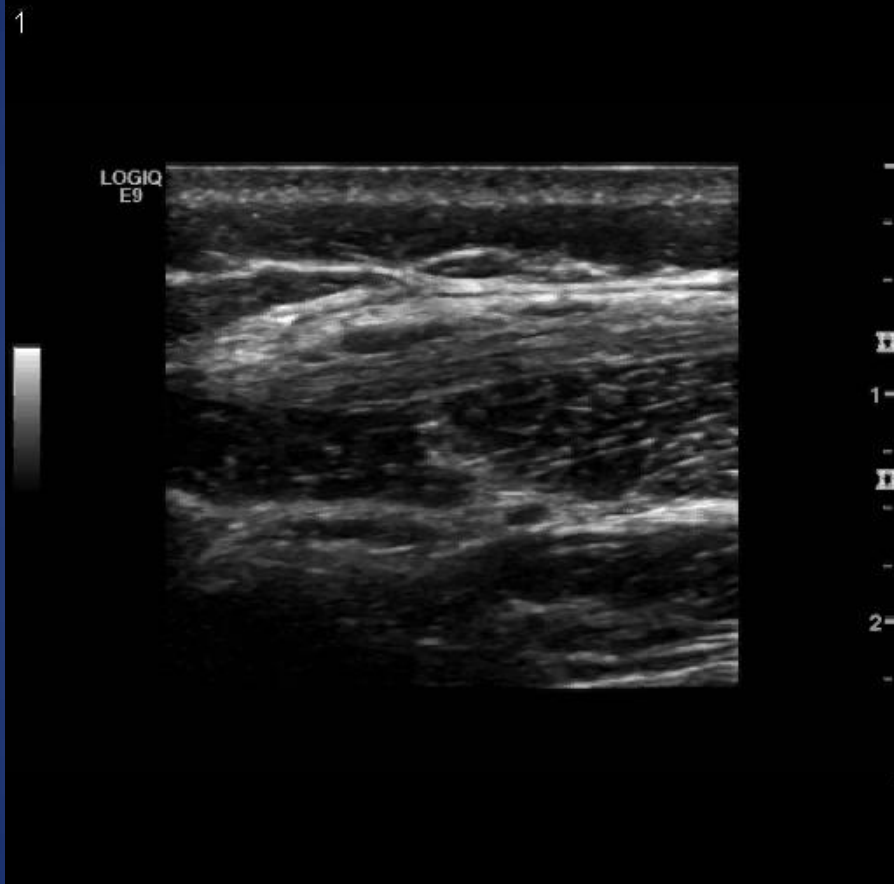
OCCIPITAL NEURALGIA



OCCIPITAL NEURALGIA

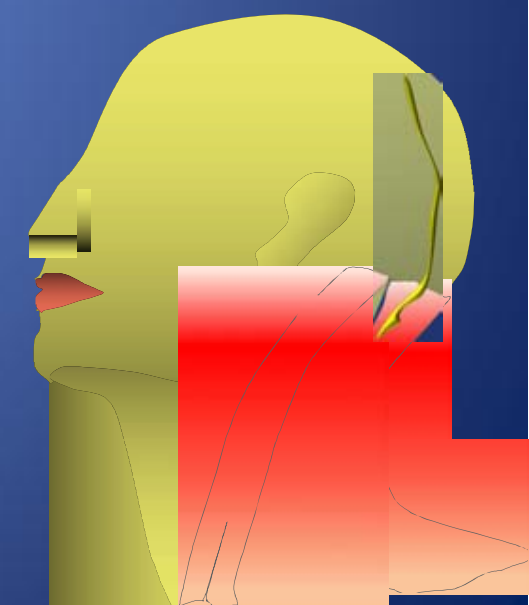
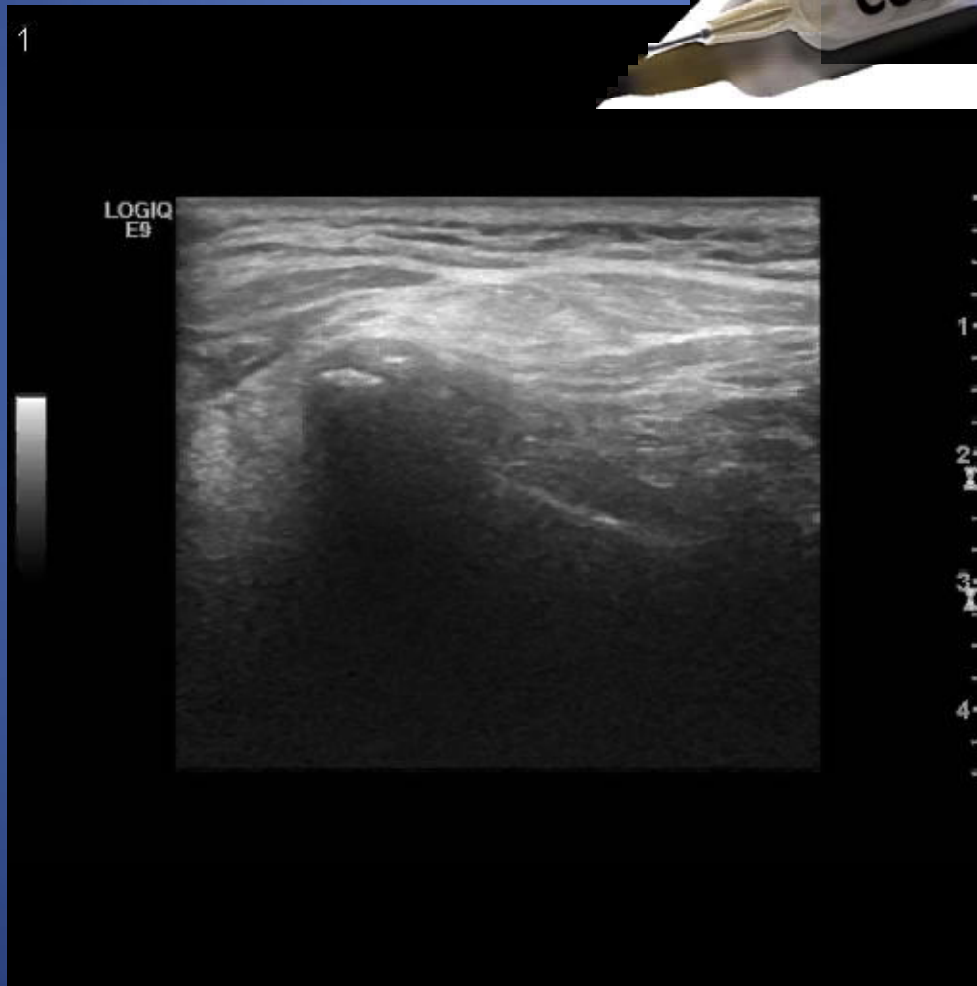
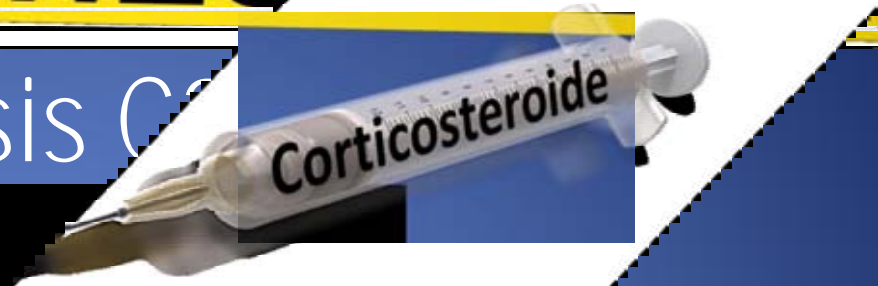

OCCIPITAL NEURAL GITA



OCCIPITAL NEURAL GITA

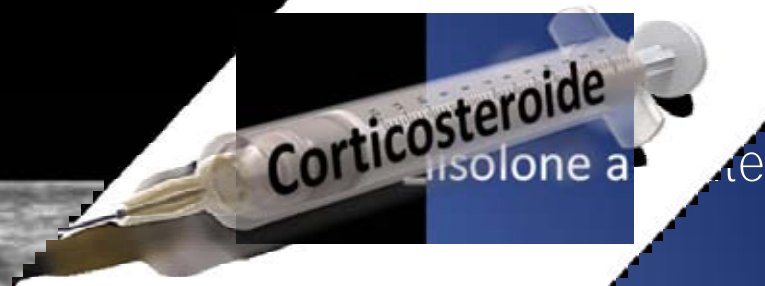
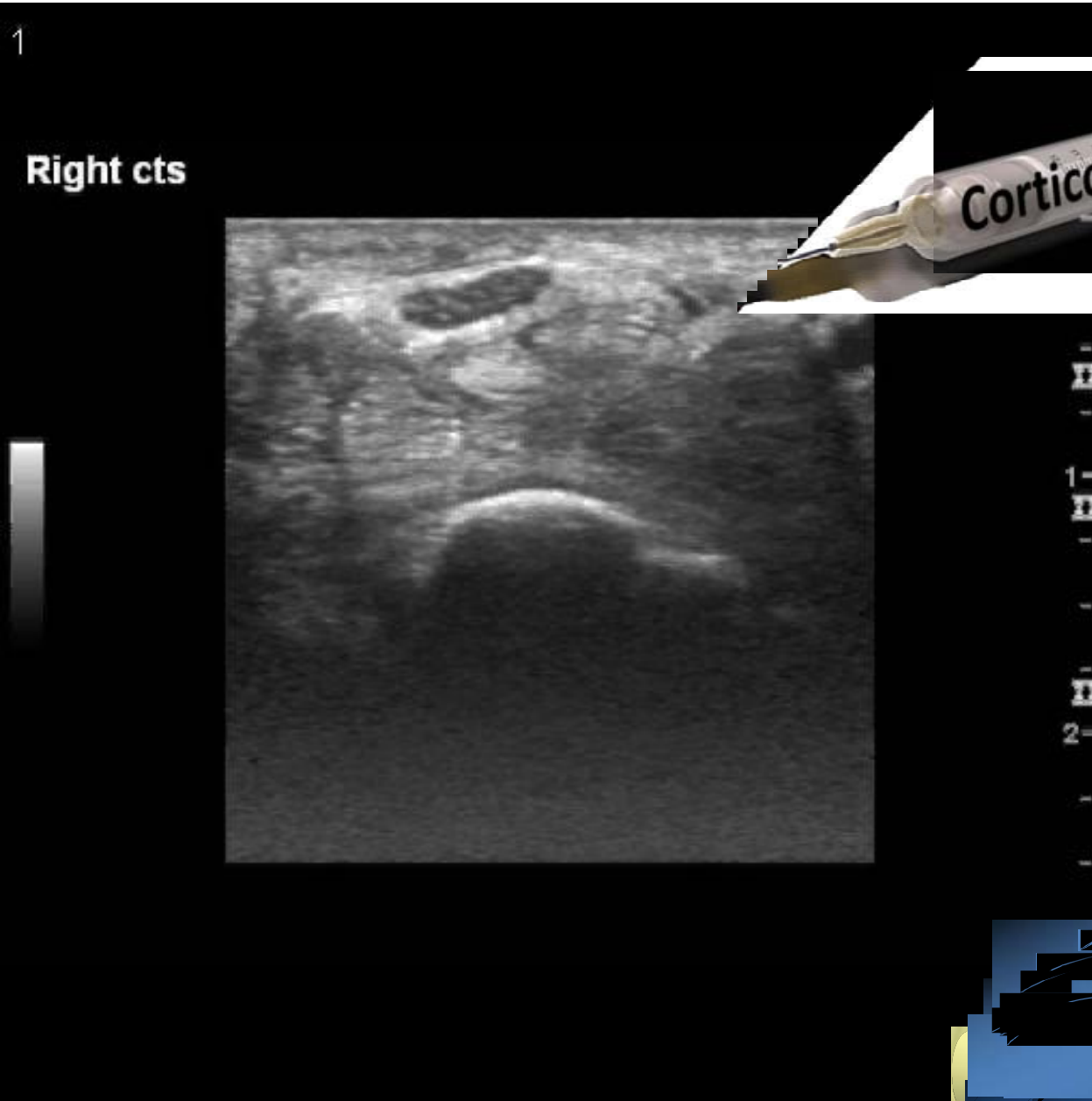
Osteoartrosis C



V. Agan

A prospective
injection

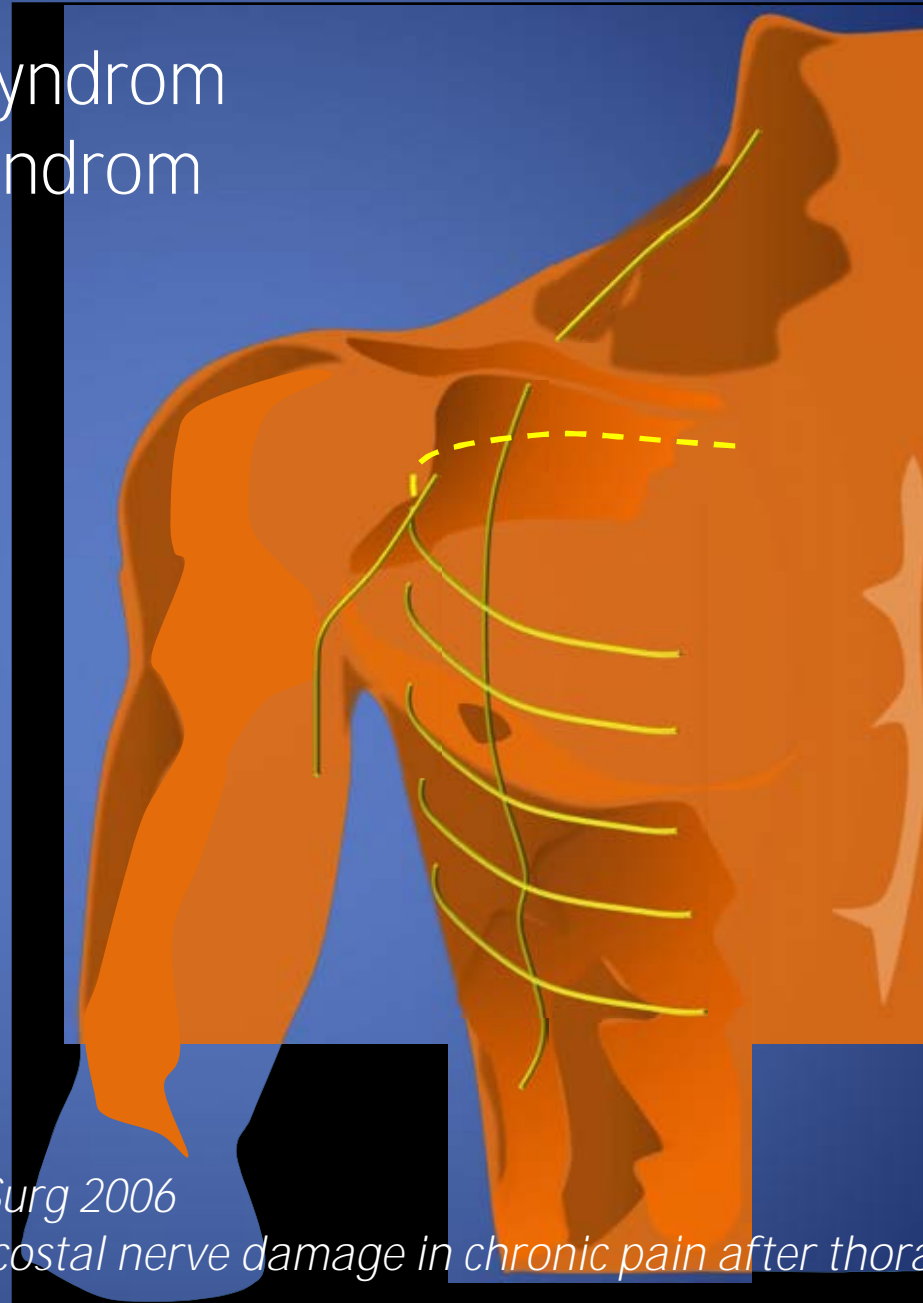
79% of



Post Thoracotomy Syndrom Post Mastectomy Syndrom

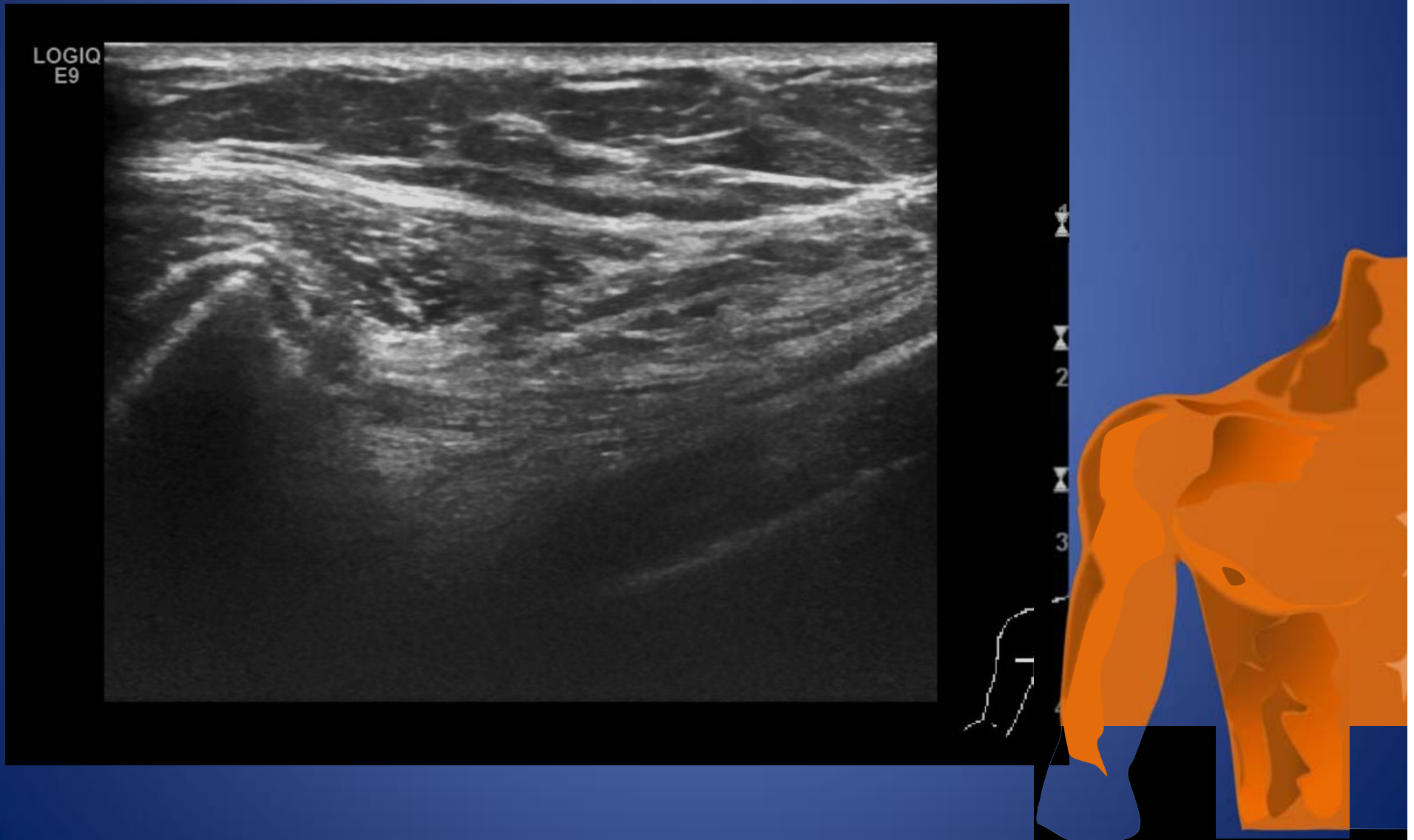
N.Thoracicus longus
N intercostalis
N intercostobrachialis
N thoracodorsalis

1. Scar neuroma?
2. Diagn Block
3. Cortison/Hyaluron

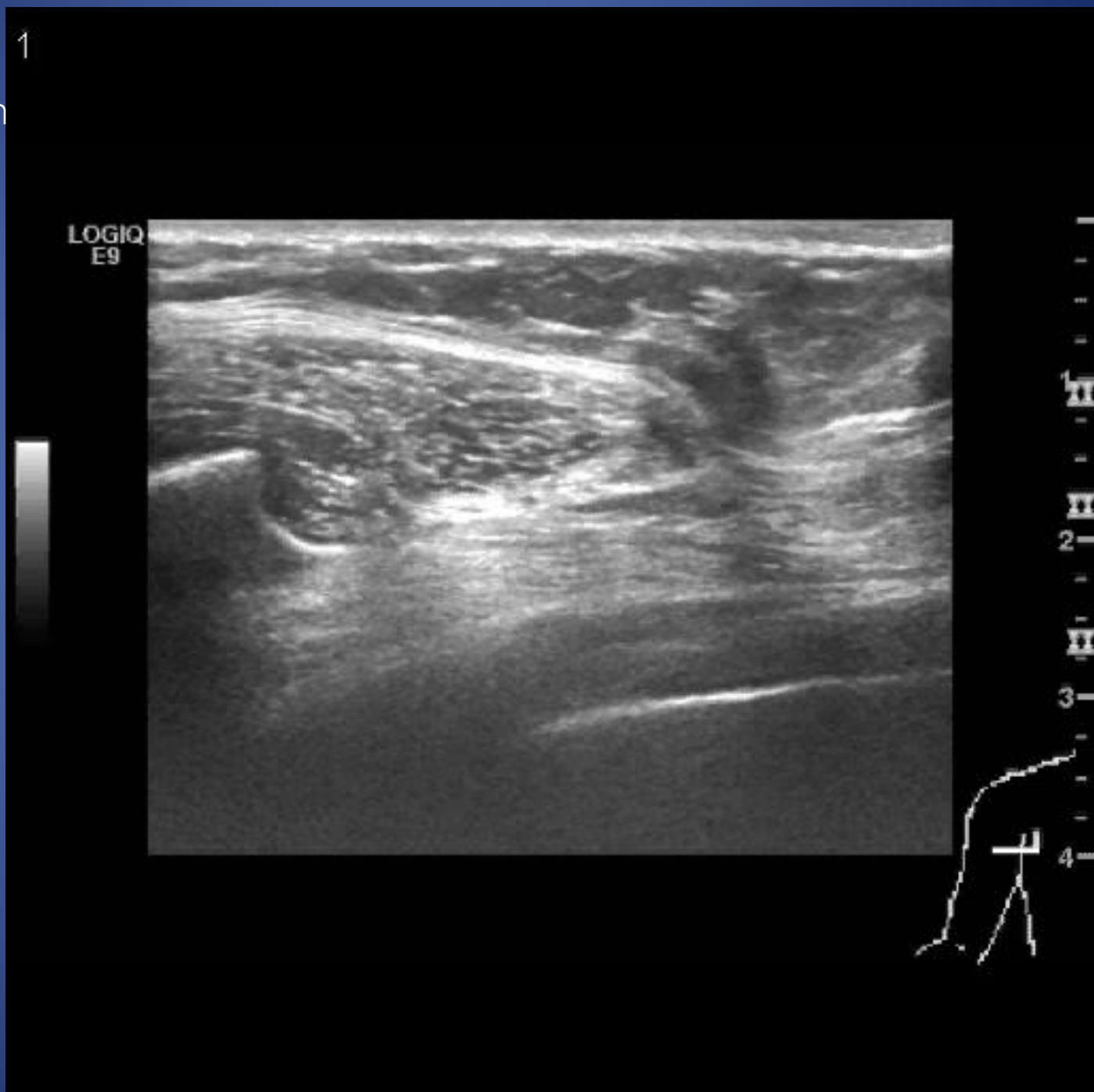


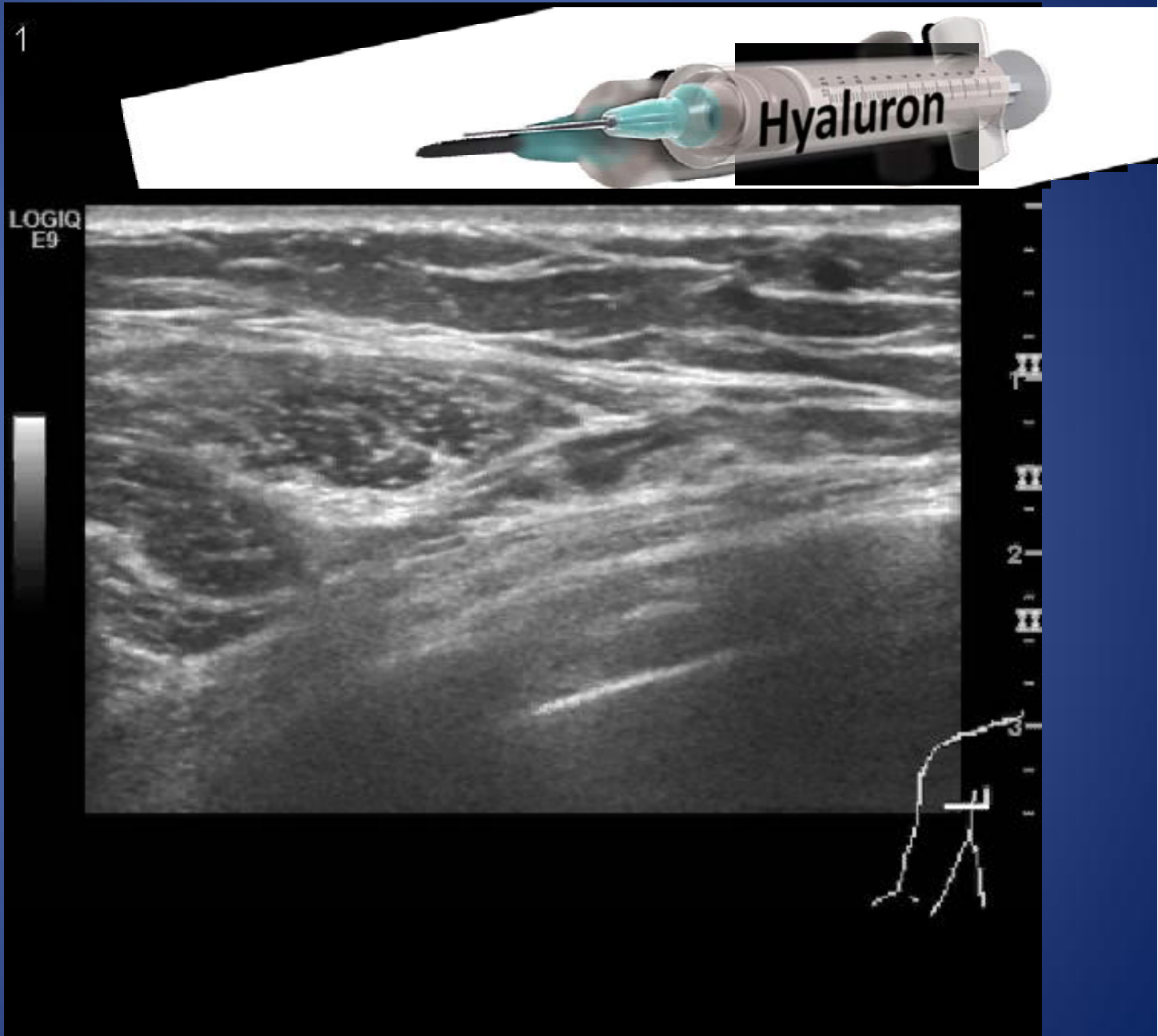
*Maguire MF Eur J Cardiothoracic Surg 2006
A study exploring the role of intercostal nerve damage in chronic pain after thoracic surgery.*

Mastectomie, Axilladisektion vor 3a
VAS 8
Kann Arm nicht bewegen



Lidocain (1ml)
Schmerzfrei für 24 h

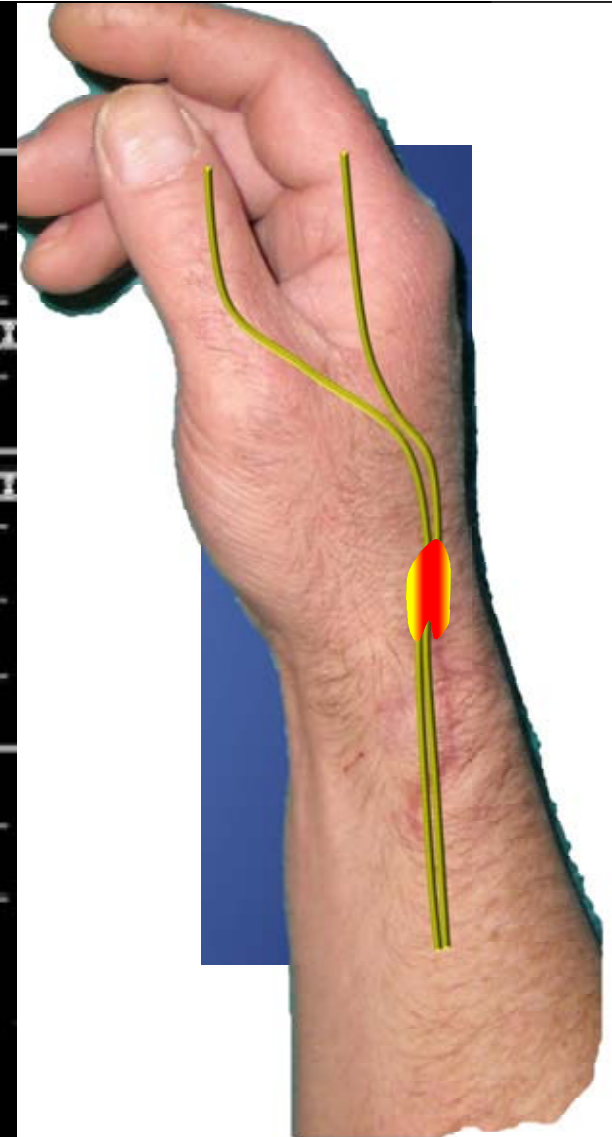
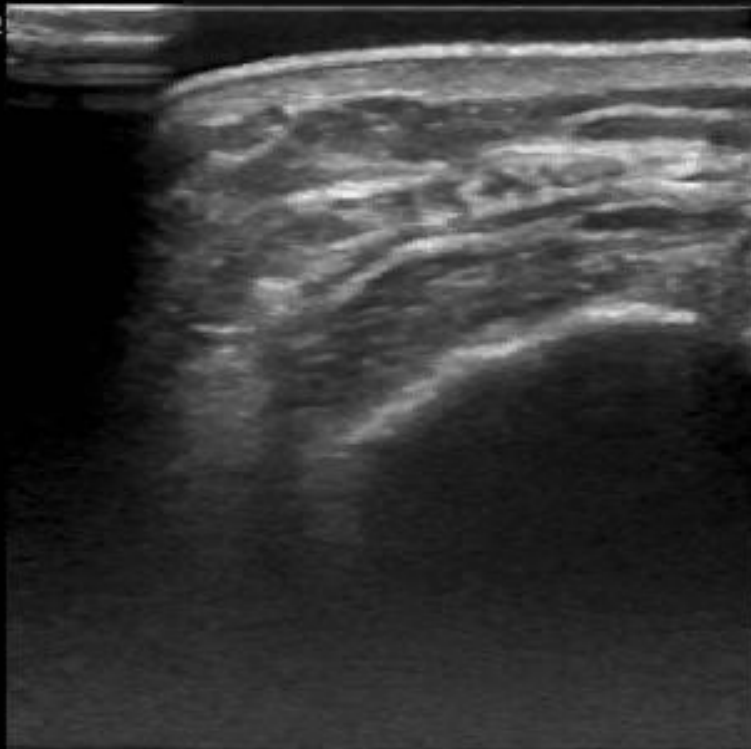




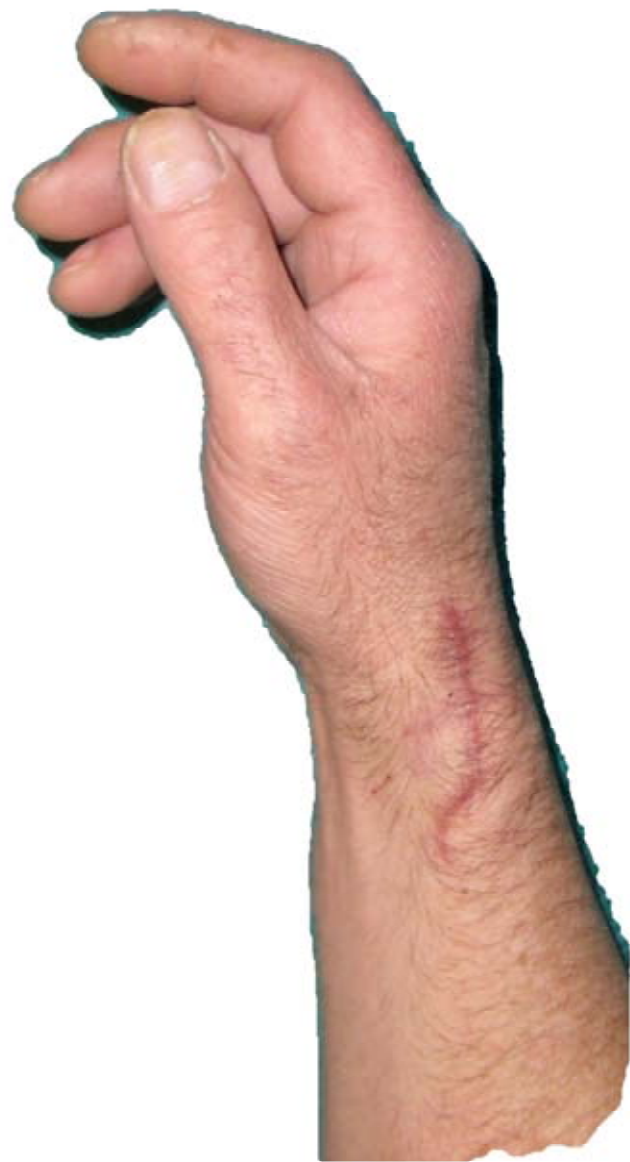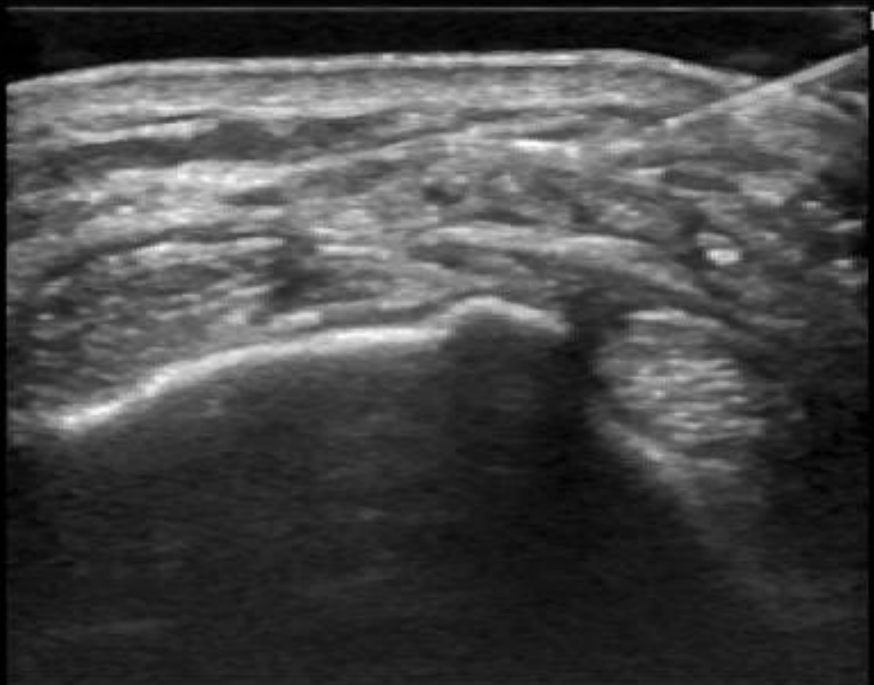
WARTENBERG SYNDROM

LEFT

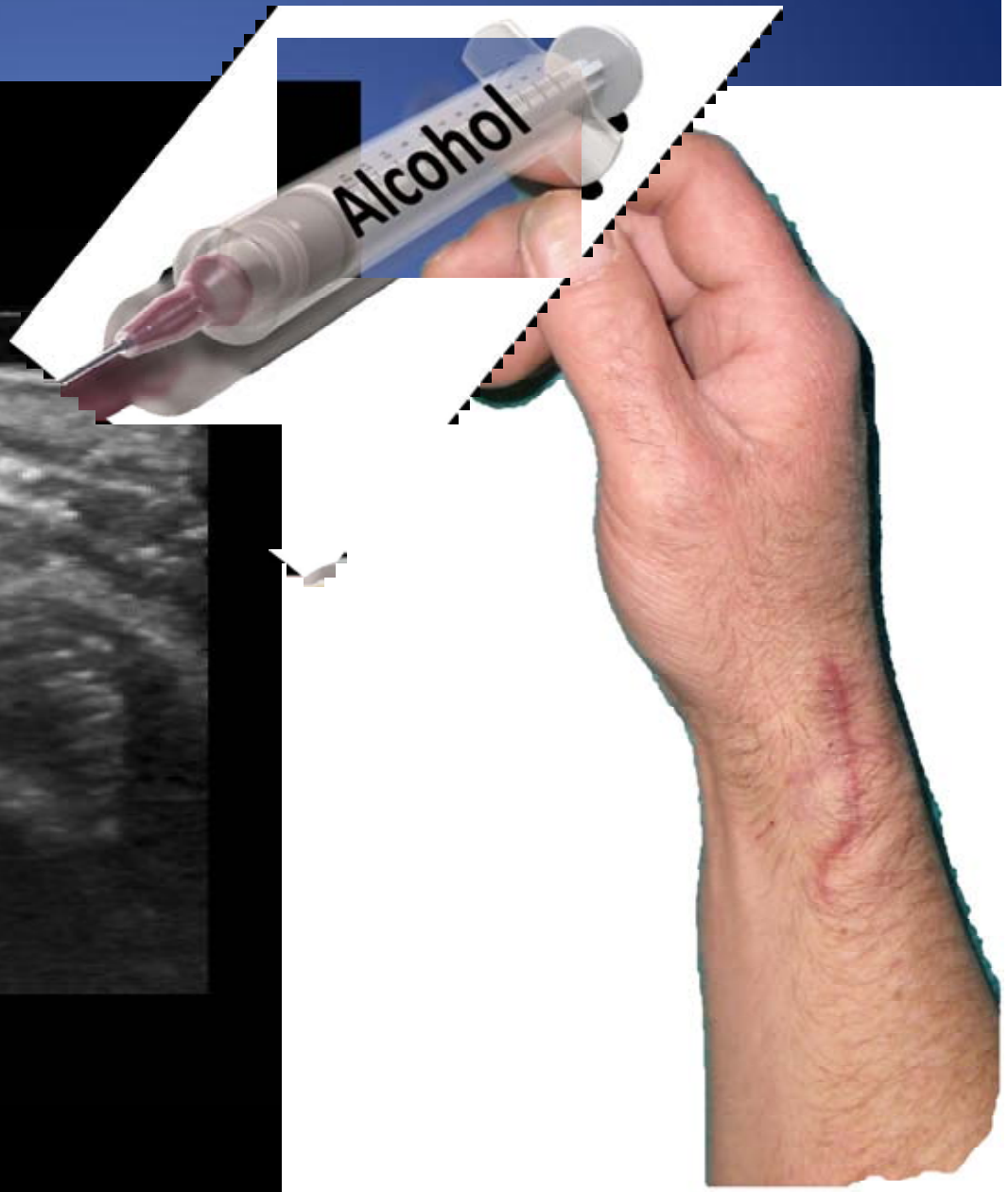
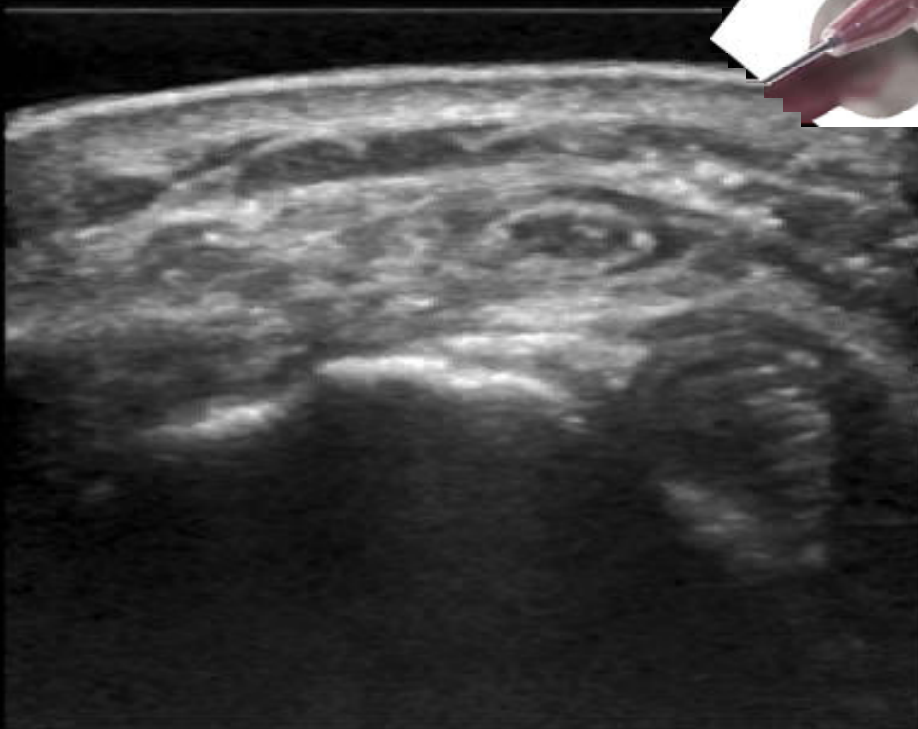
LOGIQ
E9



1



1



US –guided chemical ablation

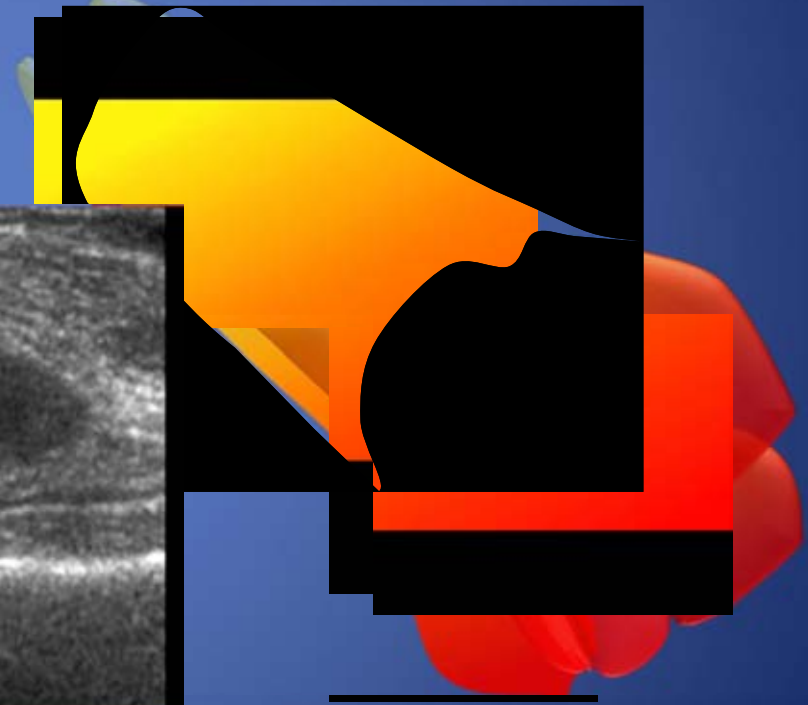
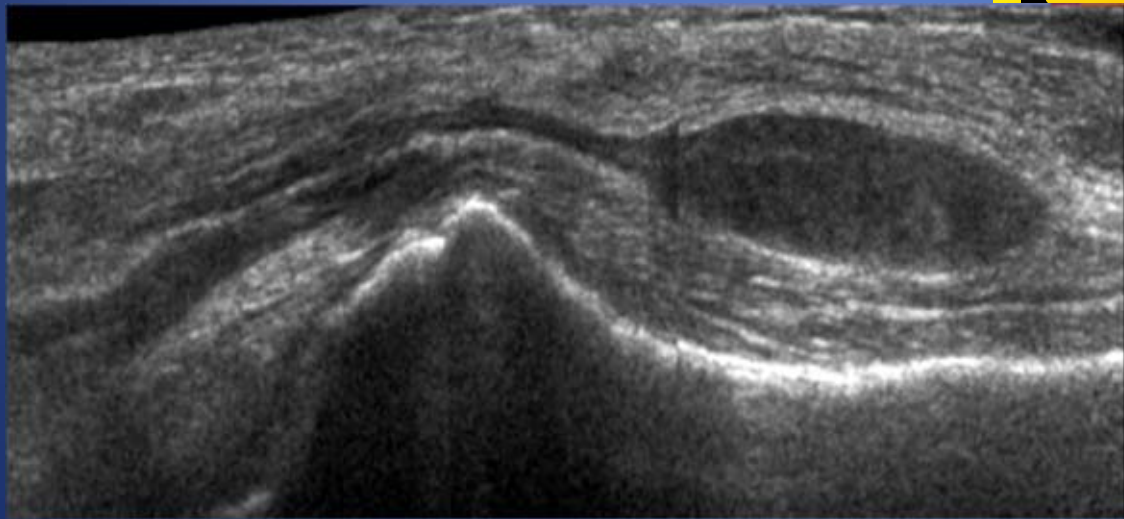
Painful stump neuroma

Phantom pain

C2

Phenol


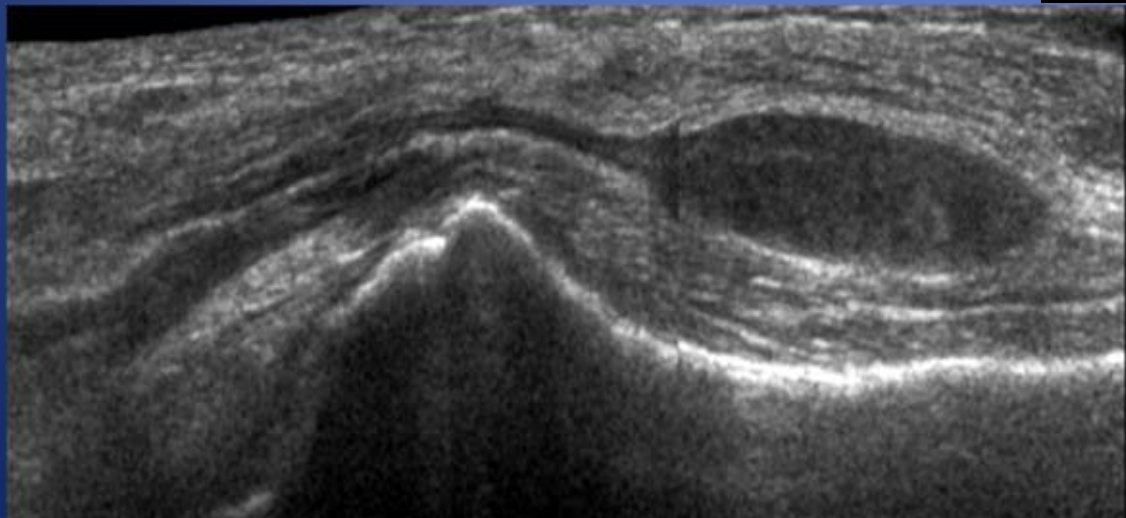
Glyzerol

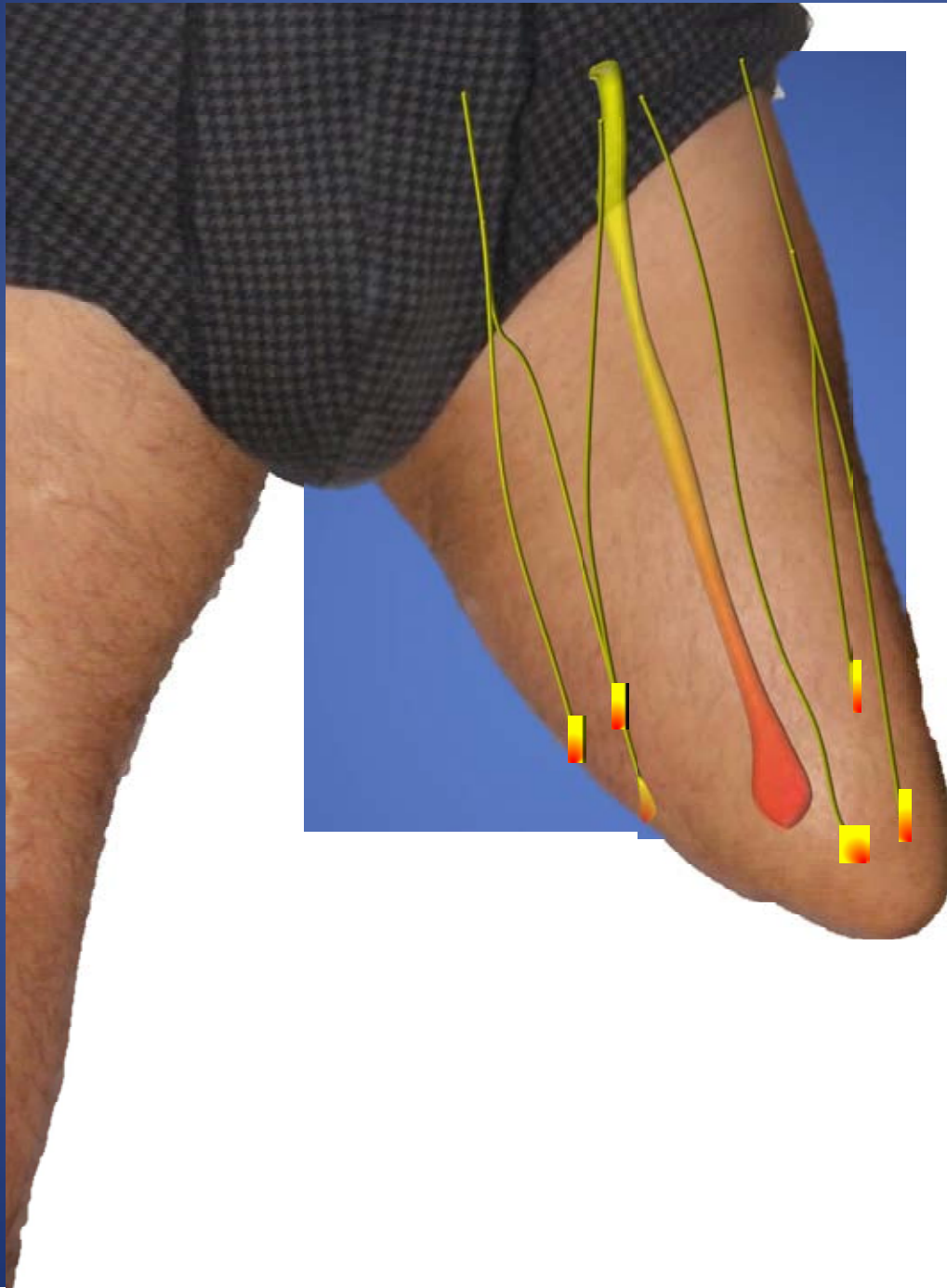


Sonographically guided phenol injection in painful stump neuroma. Gruber H,,
Bodner G.AJR Am J Roentgenol. 2004

US –guided thermal ablation

Radiofrequency (pulsed/thermal)
Cryoablation



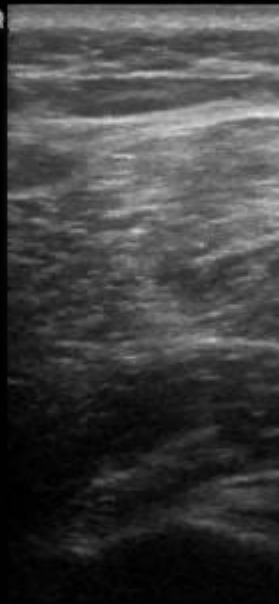


1

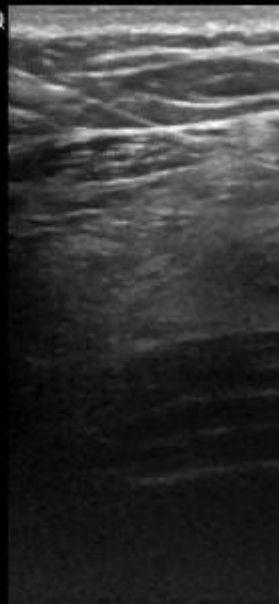1

1

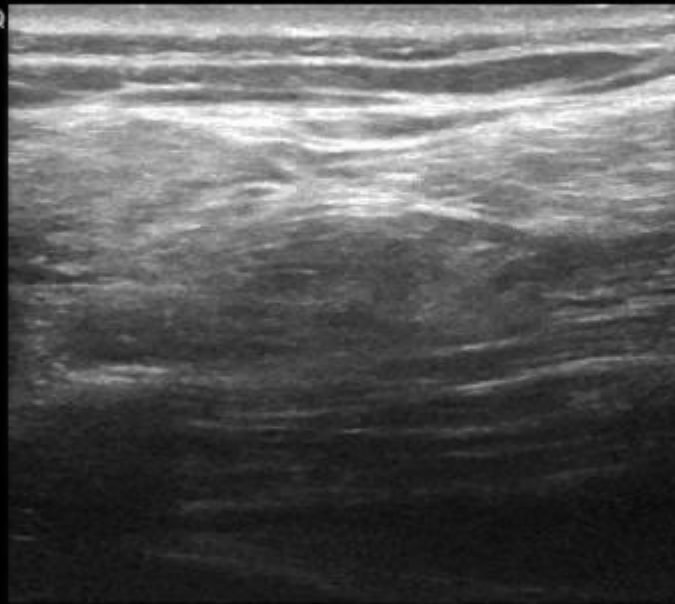
LOGIQ
E9

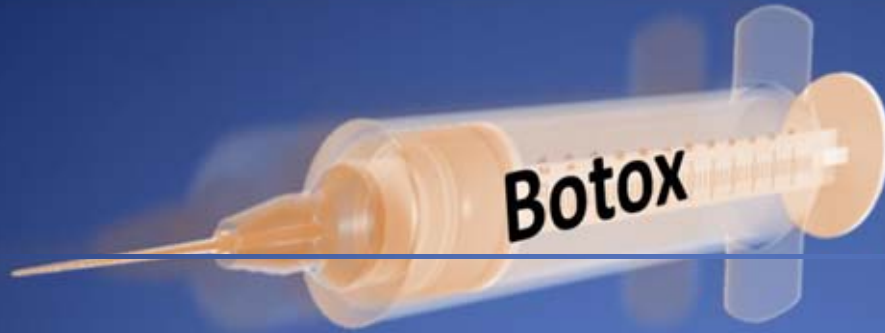

LOGIQ
E9



LOGIQ
E9





Spasticity

Obstetric brachial plexus palsy

Hypertrophic/abnormal muscles

Scalenus Syndrom (Thoracic Outlet Syndrom)

Subclavius/Serratus/Omohyoideus/Axillary arch

Pronator teres Syndrom

Long belly Syndrom

M anconeopitrochlearis

Piriformis Syndrom

Tarsal Tunnel Syndrom (Soleus)

Torriani M. Skeletal Radiol. 2010

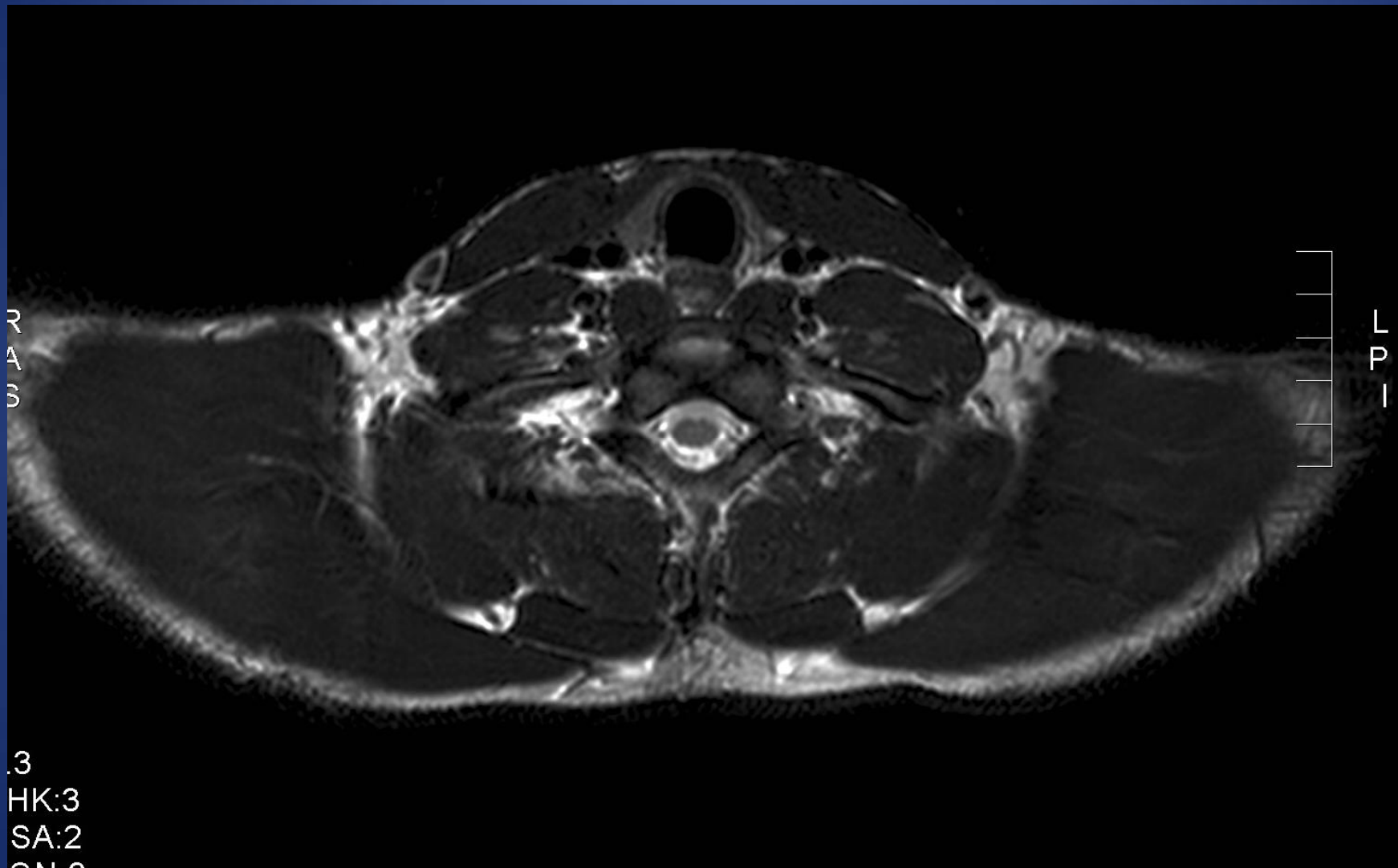
Botulinum toxin injection in neurogenic thoracic outlet syndrome: results and experience using a ultrasound-guided approach.

RESULTS:

Forty-one subjects with suspected NTOS underwent a total of 92 injections (58 anterior scalene, 33 pectoralis minor, and 1 subclavius muscle). Technical success was achieved in all procedures. No complications occurred. Symptom improvement occurred after 69% of procedures.

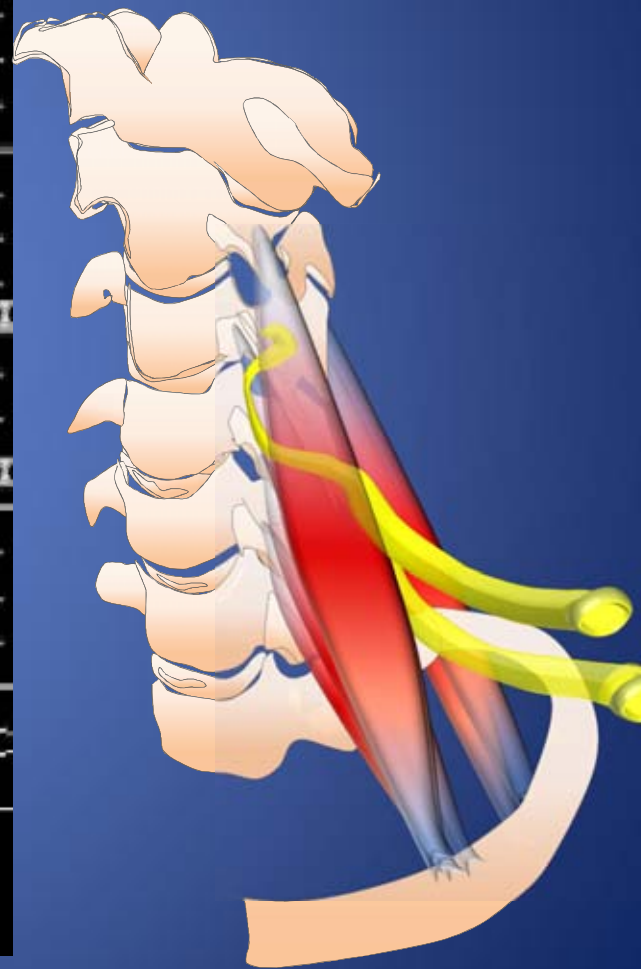
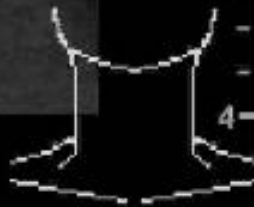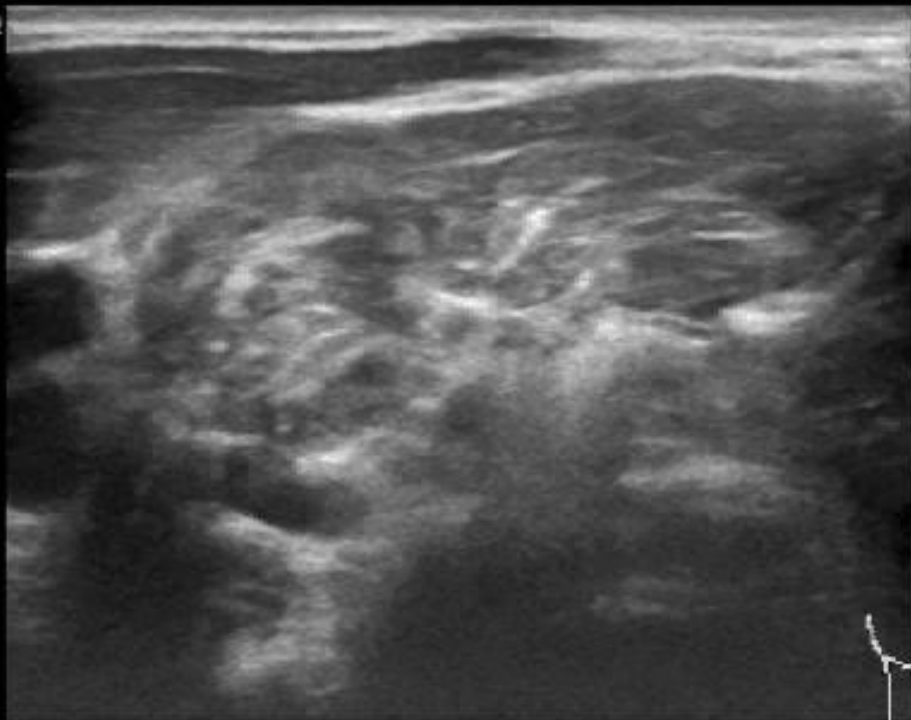
The VAS before and after the procedure changed from 7.1 to 2.8

Scalenus minimus-Syndrom



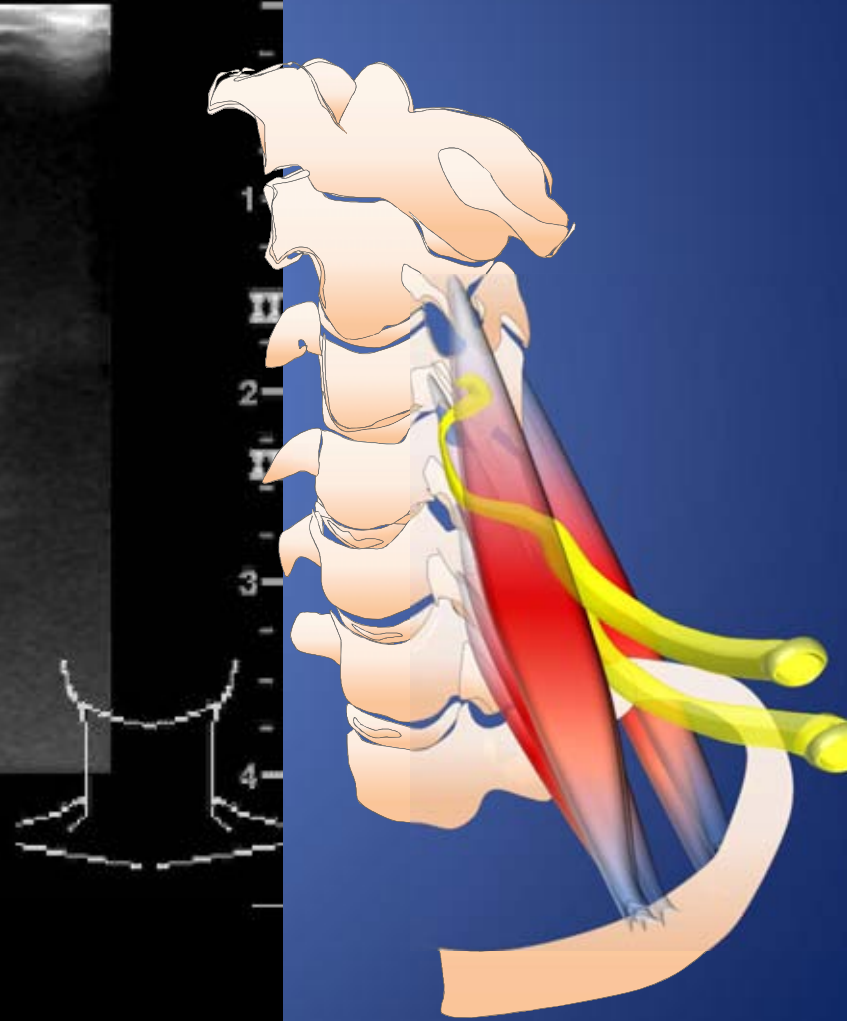
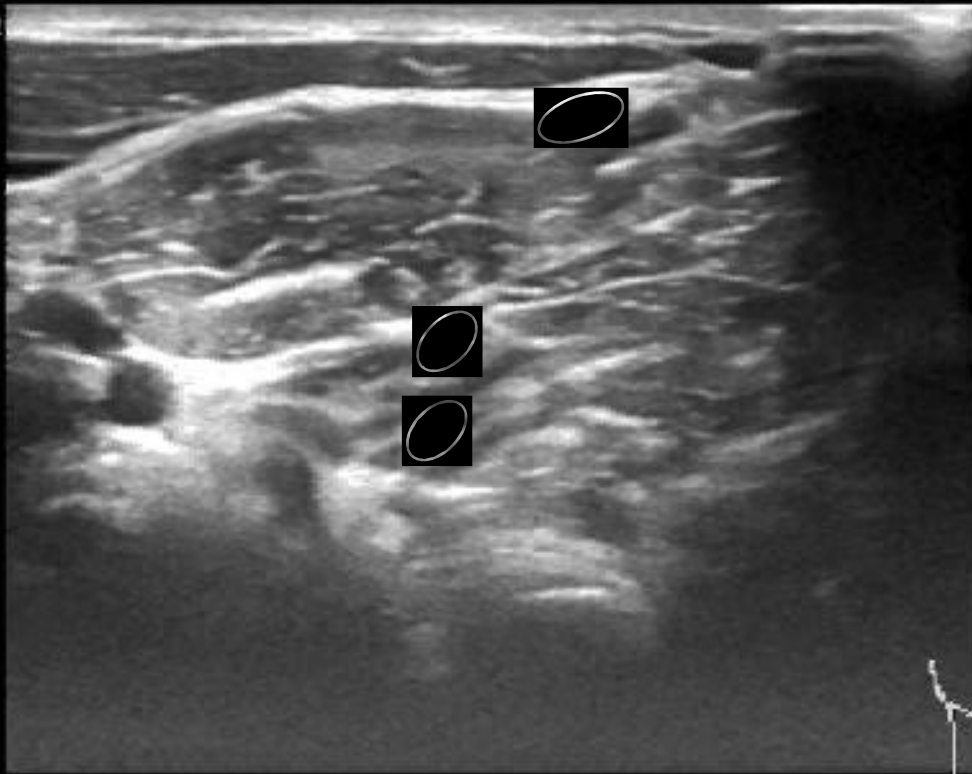
1

LOGIQ
E9



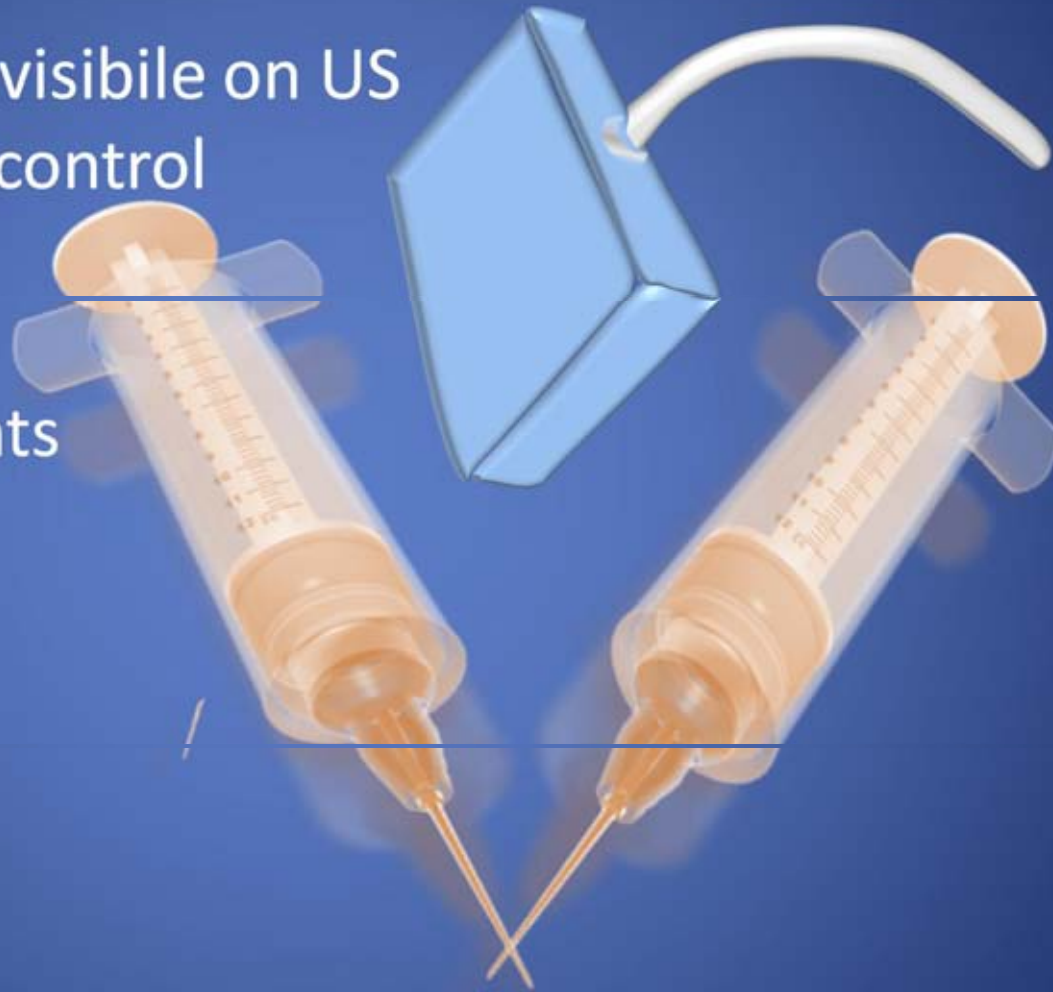
1


LOGIQ
E9



Conclusion

- Peripheral nerve visible on US
- Excellent needle control
- Minimal dosis
- Early diagnosis
- Therapeutic agents





on peripheral neuropathies

Save the date
22-24 May 2014



MAY 24-26, 2014, VIENNA
3RD INTERNATIONAL
CONFERENCE & COURSE ON
NEUROMUSCULAR
ULTRASOUND



www.ispni.org

International Society of
Peripheral Neurophysiologic Imaging